


BROKEN FRACTURE



NORMAL



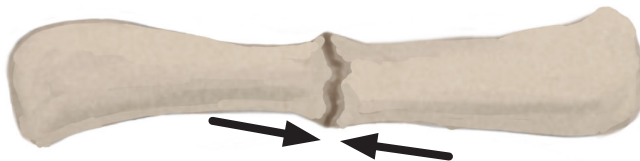
NON-DISPLACED



DISPLACED



COMMINUTED



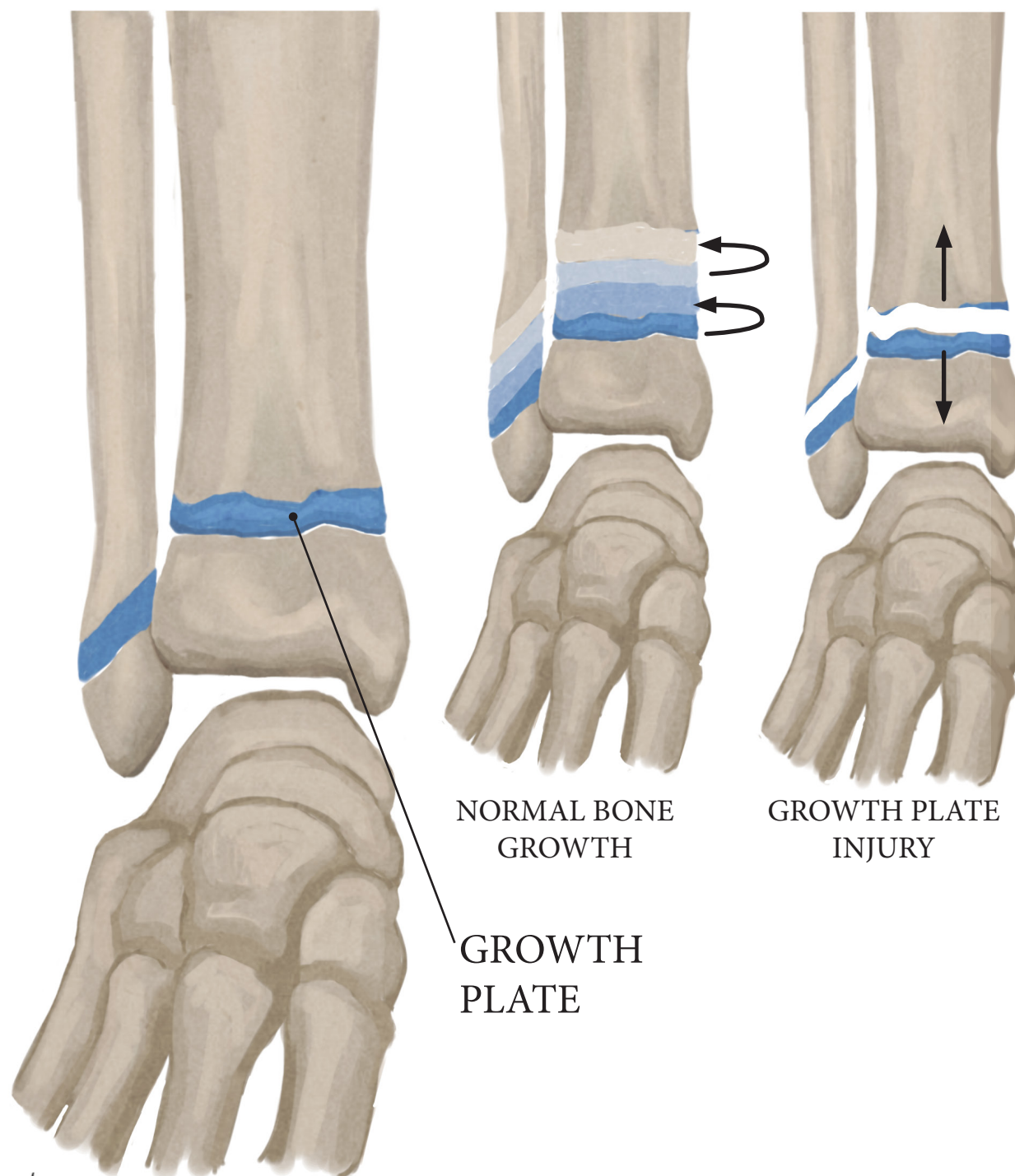
BUCKLE



DISLOCATION

S. ADHIKARI
M.D.

GROWTH PLATE INJURY

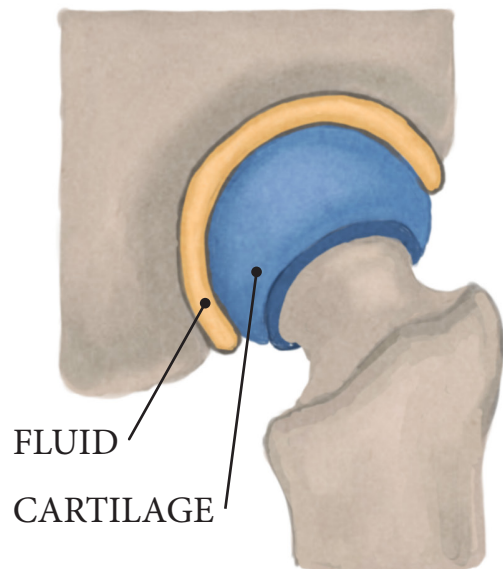


S. ADHIKARI
M.D.

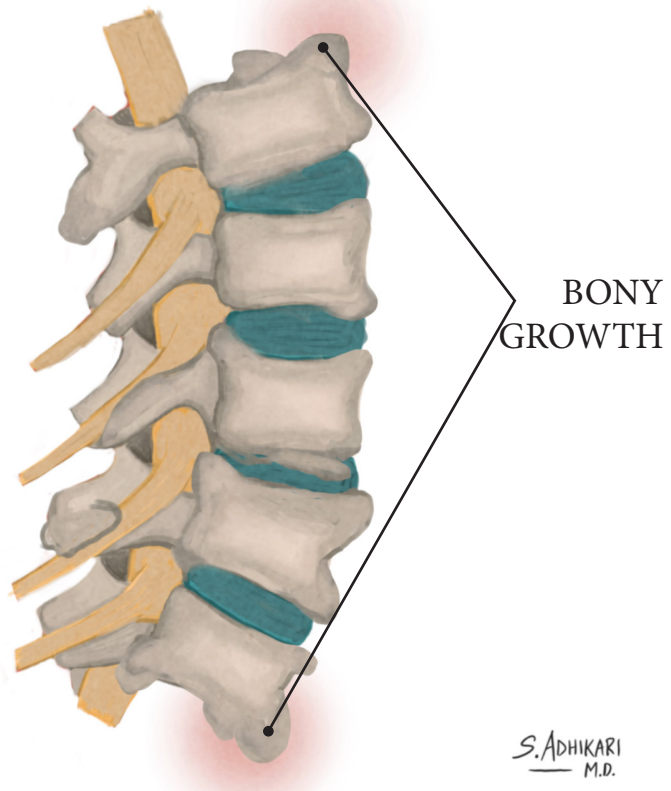
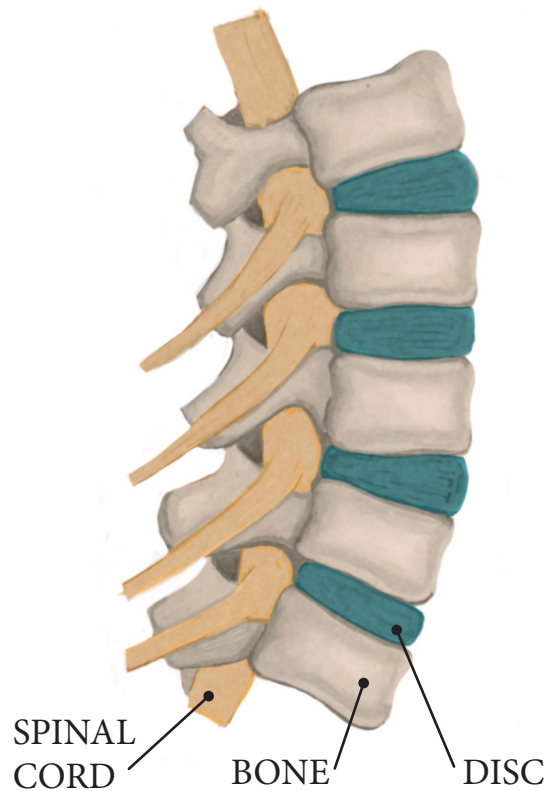
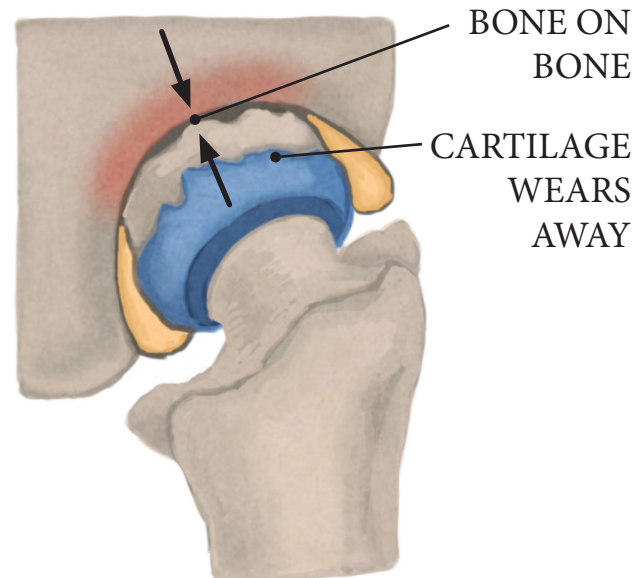
ARTHRITIS

DEGENERATIVE JOINT DISEASE

NORMAL



ARTHRITIS

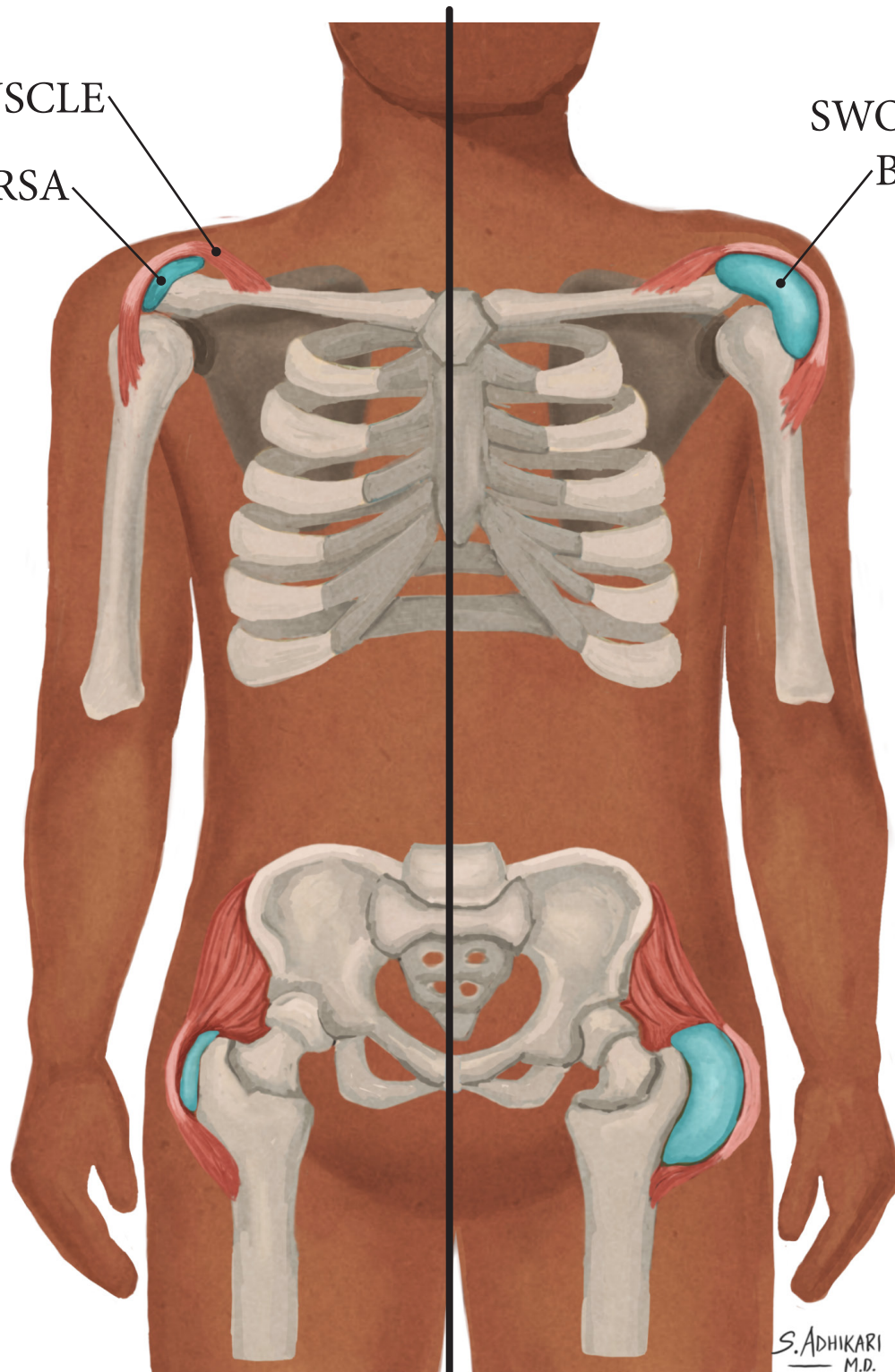


S. ADHIKARI
M.D.

BURSITIS

MUSCLE
BURSA

SWOLLEN
BURSA

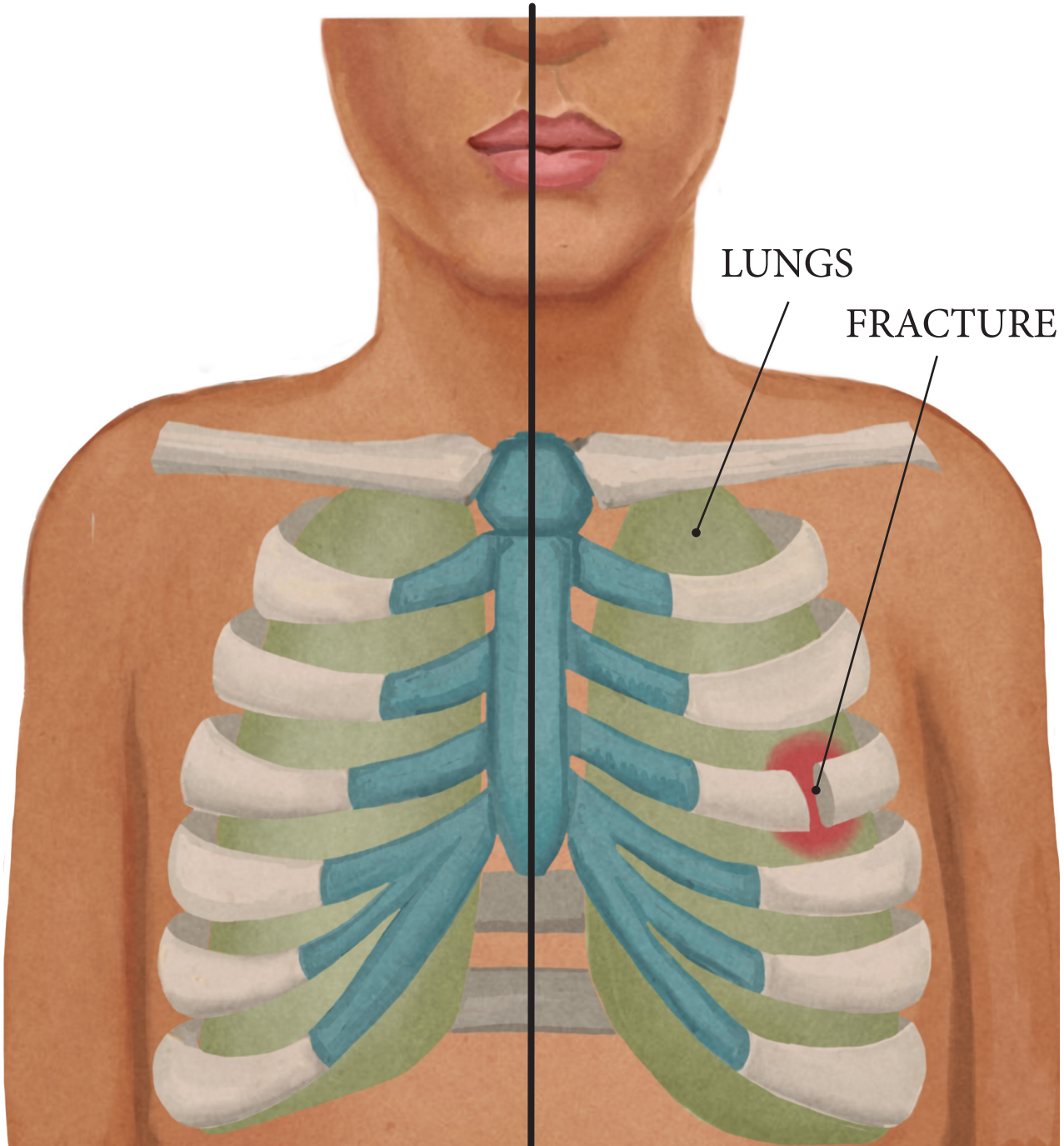


NORMAL

BURSITIS

S. ADHIKARI
M.D.

RIB FRACTURE



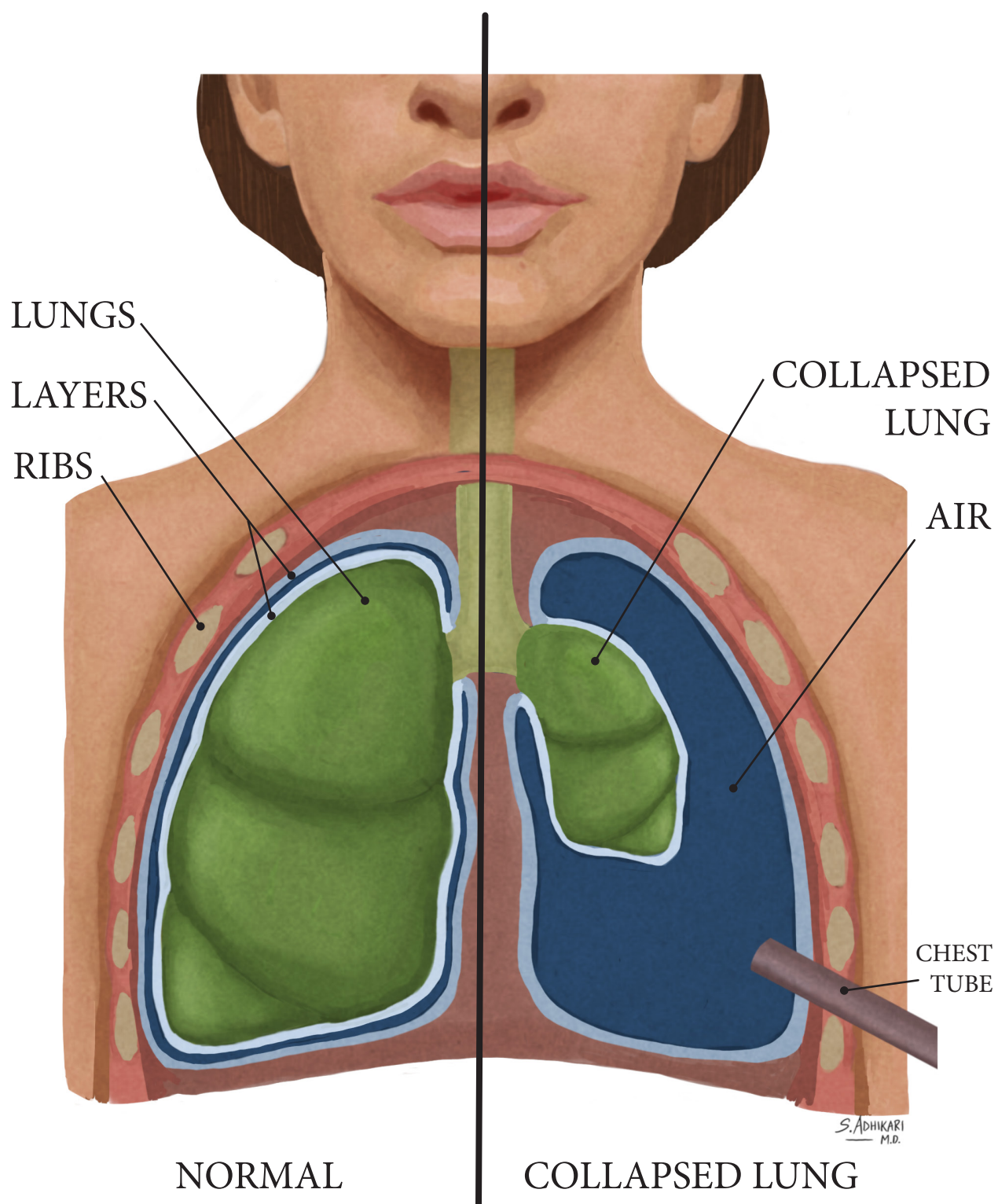
NORMAL

RIB FRACTURE

S. ADHIKARI
M.D.

COLLAPSED LUNG

PNEUMOTHORAX

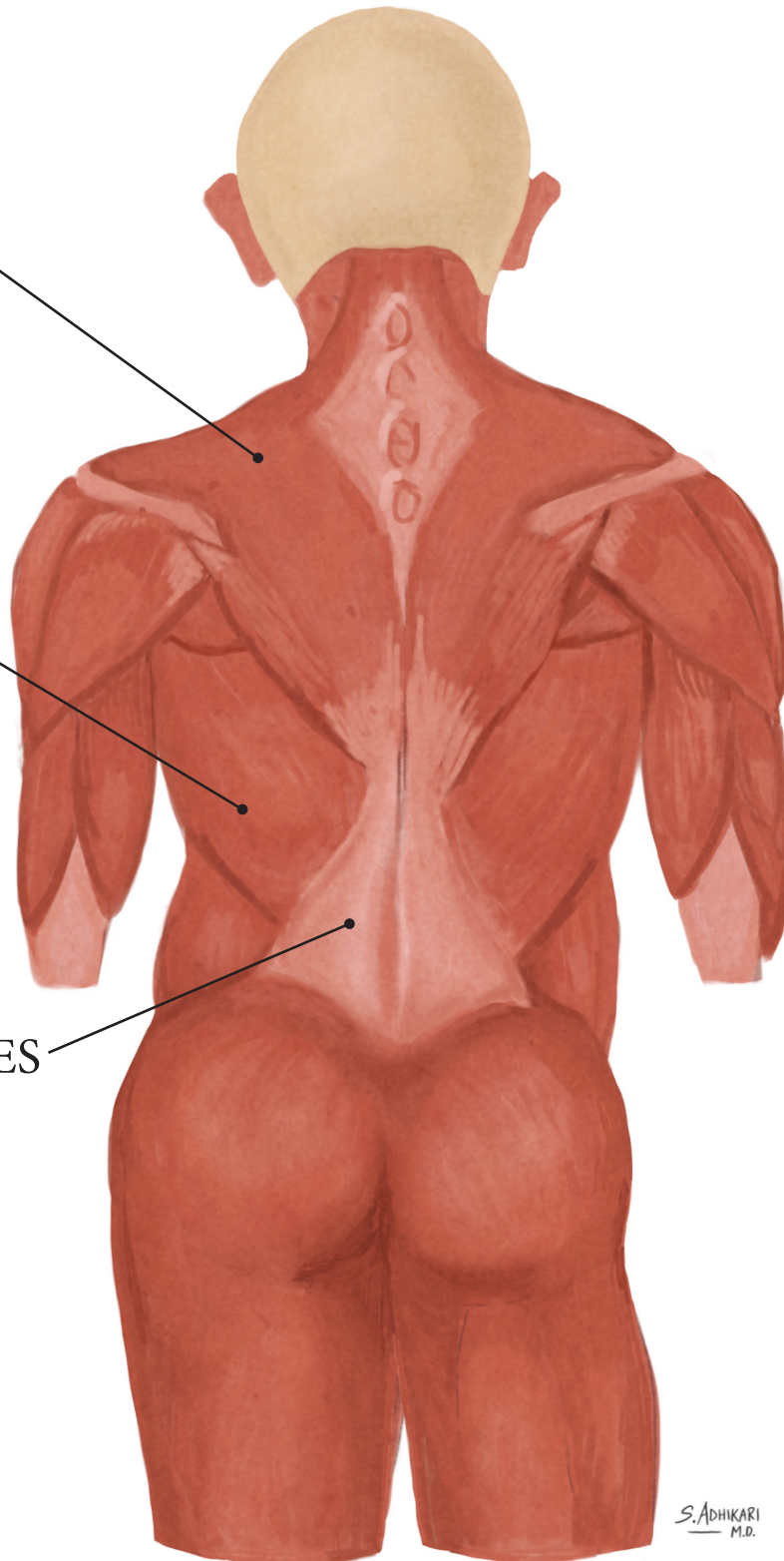


BACK PAIN MUSCULOSKELETAL

TRAPEZIUS
MUSCLE

LATISSIMUS
DORSI

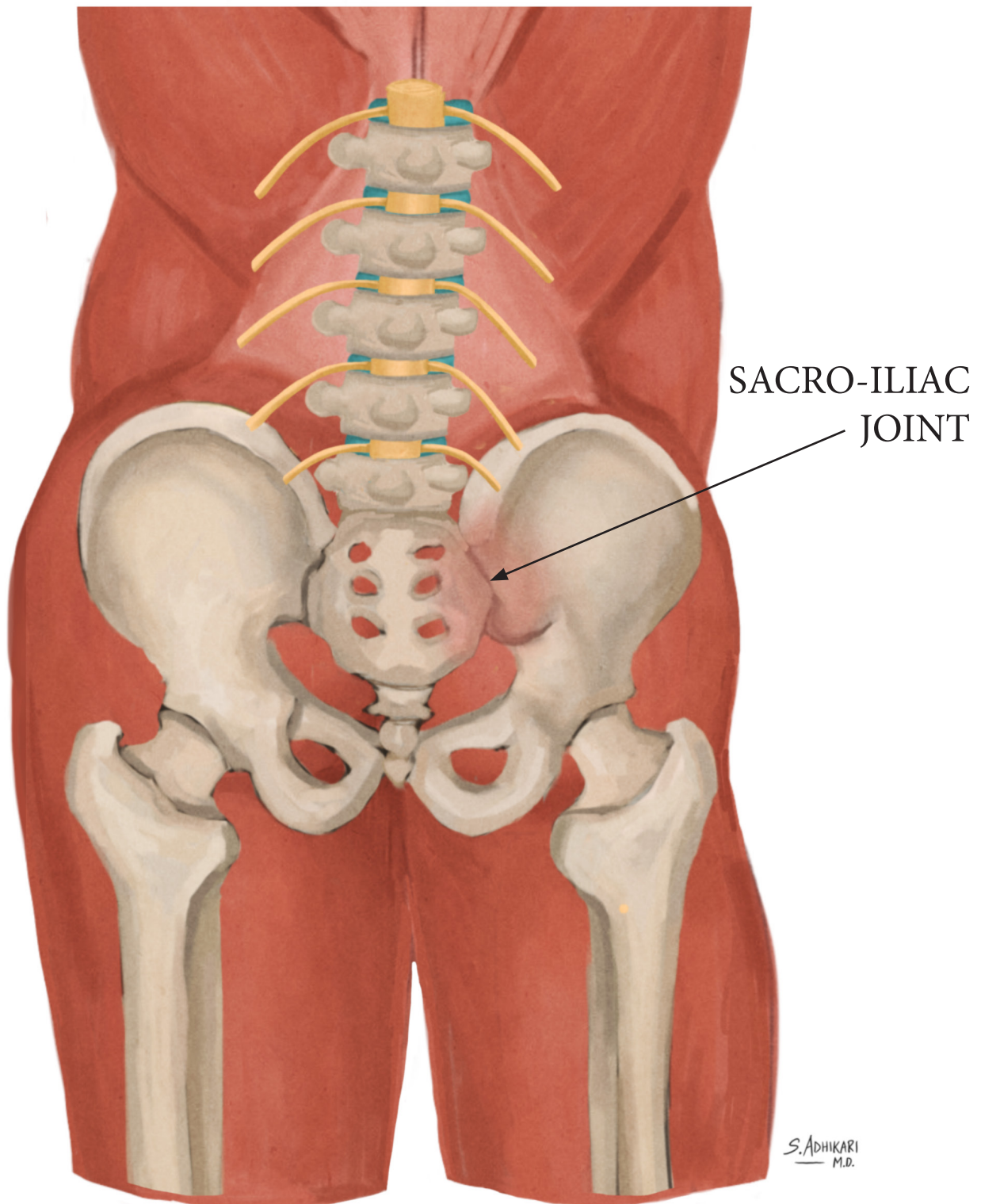
LUMBAR
BACK MUSCLES



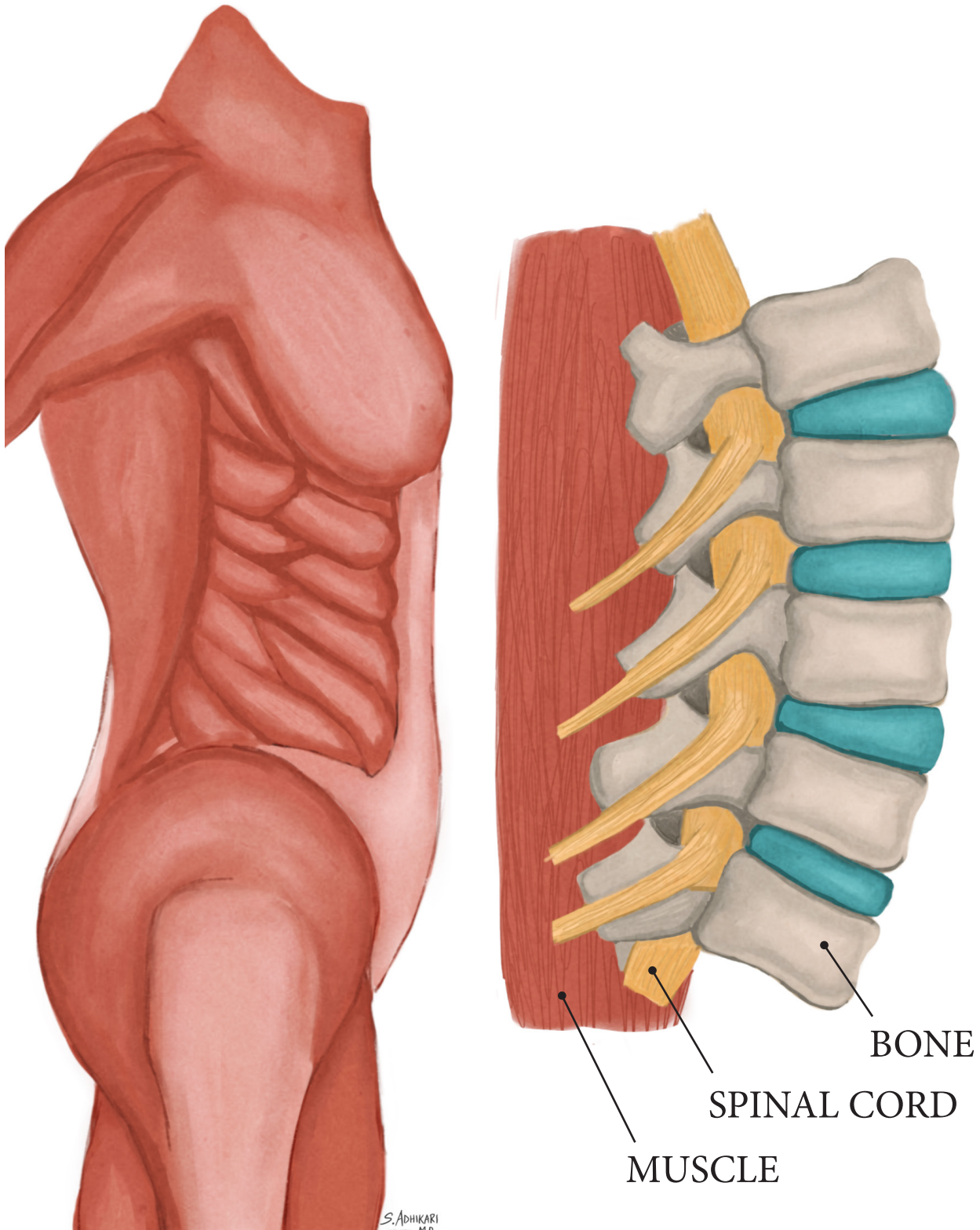
S. ADHIKARI
— M.D.

BACK PAIN

SACROILIITIS

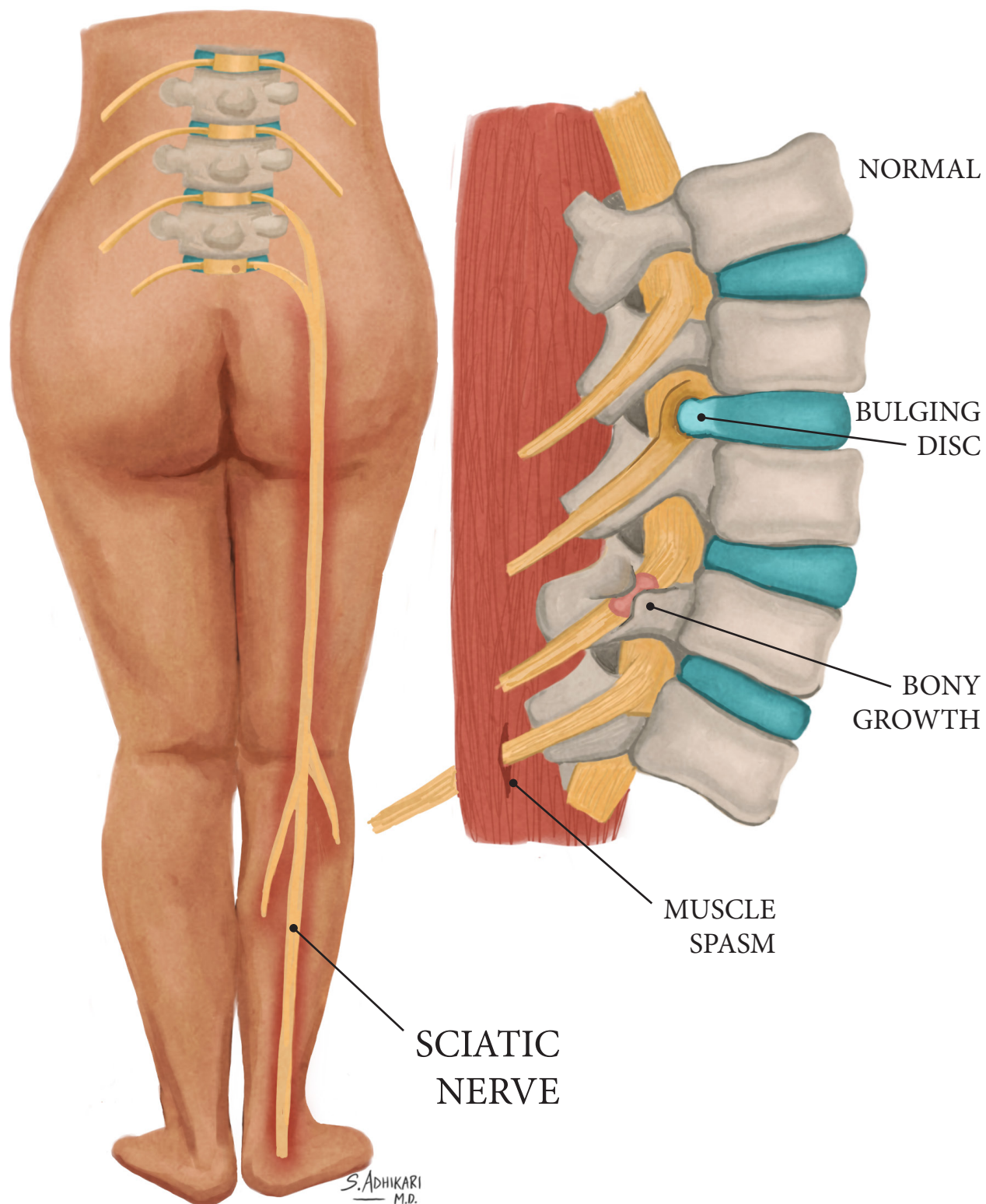


BACK PAIN SIDE VIEW

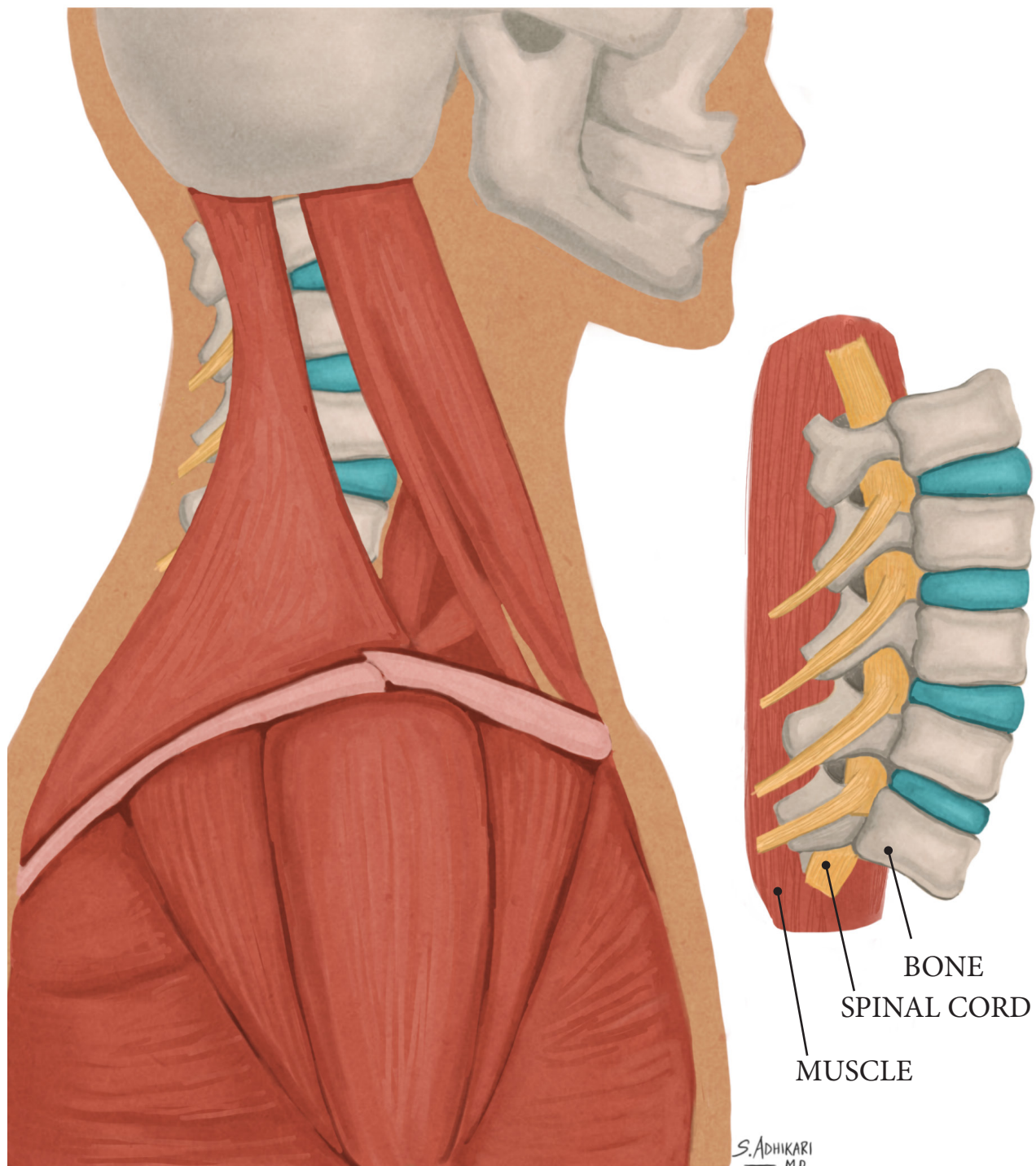


SCIATICA

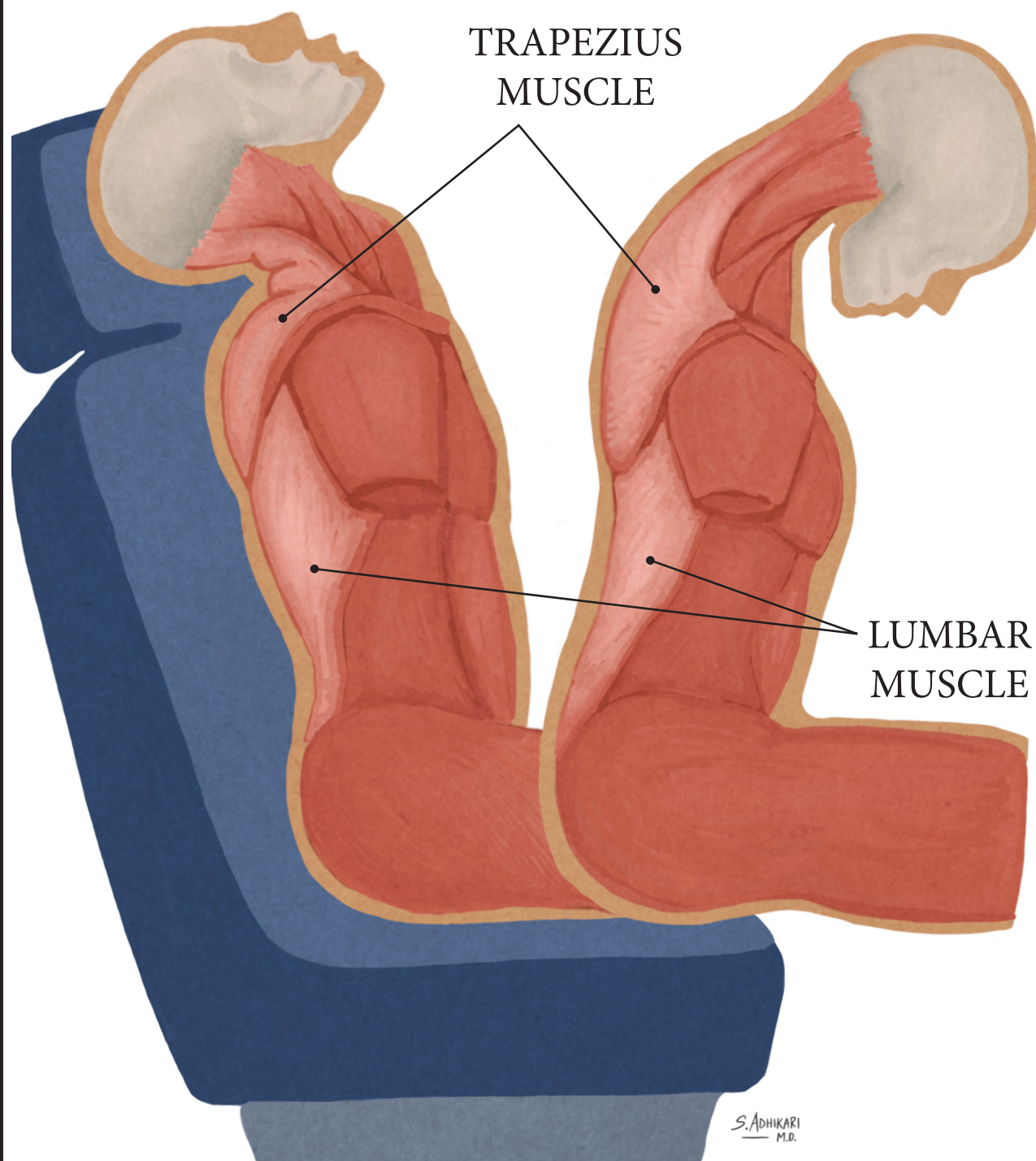
LUMBAR RADICULOPATHY



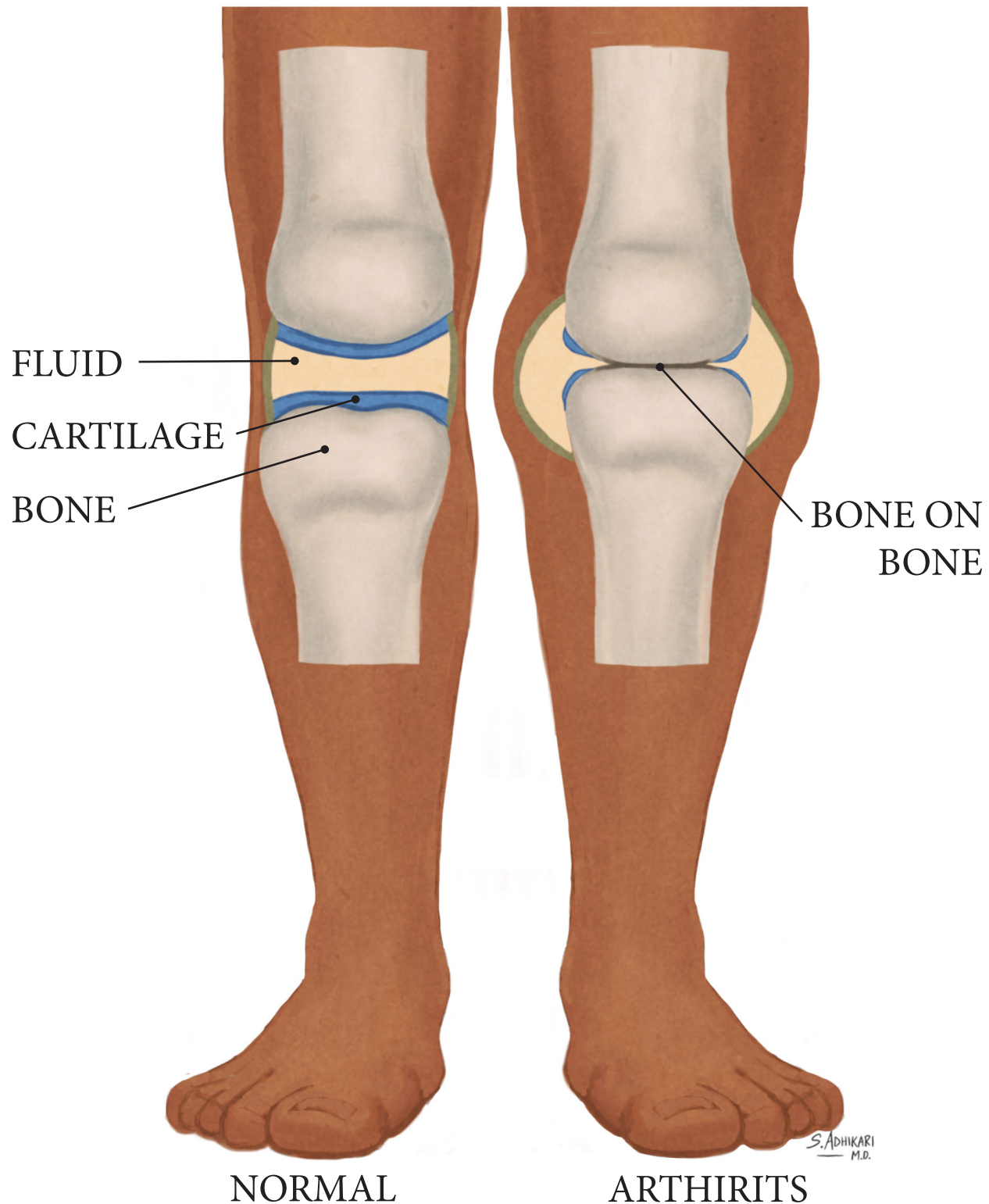
NECK PAIN CERVICAL STRAIN



NECK & BACK STRAIN MOTOR VEHICLE ACCIDENT (MVA)

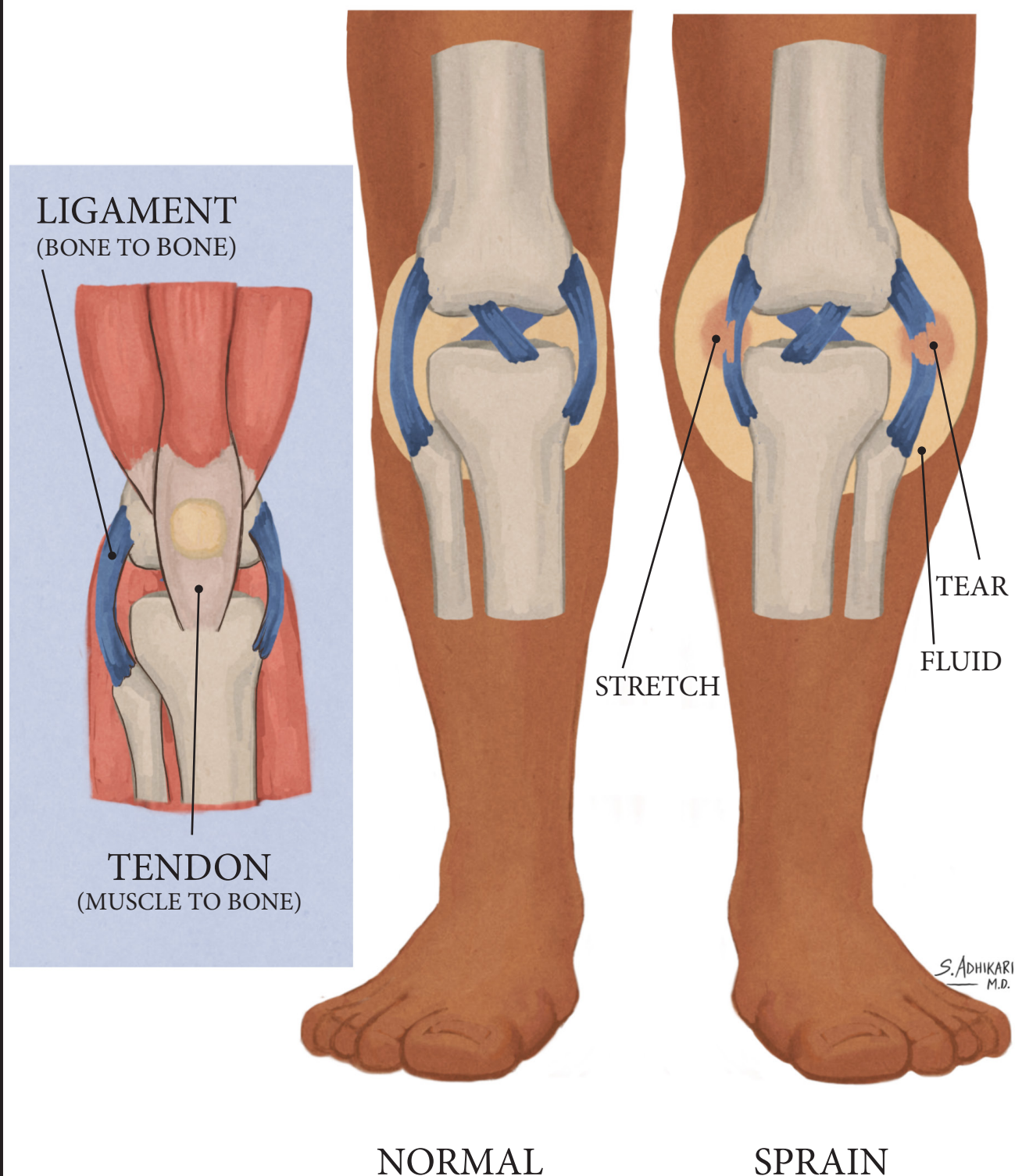


KNEE ARTHRITIS OSTEOARTHRITIS



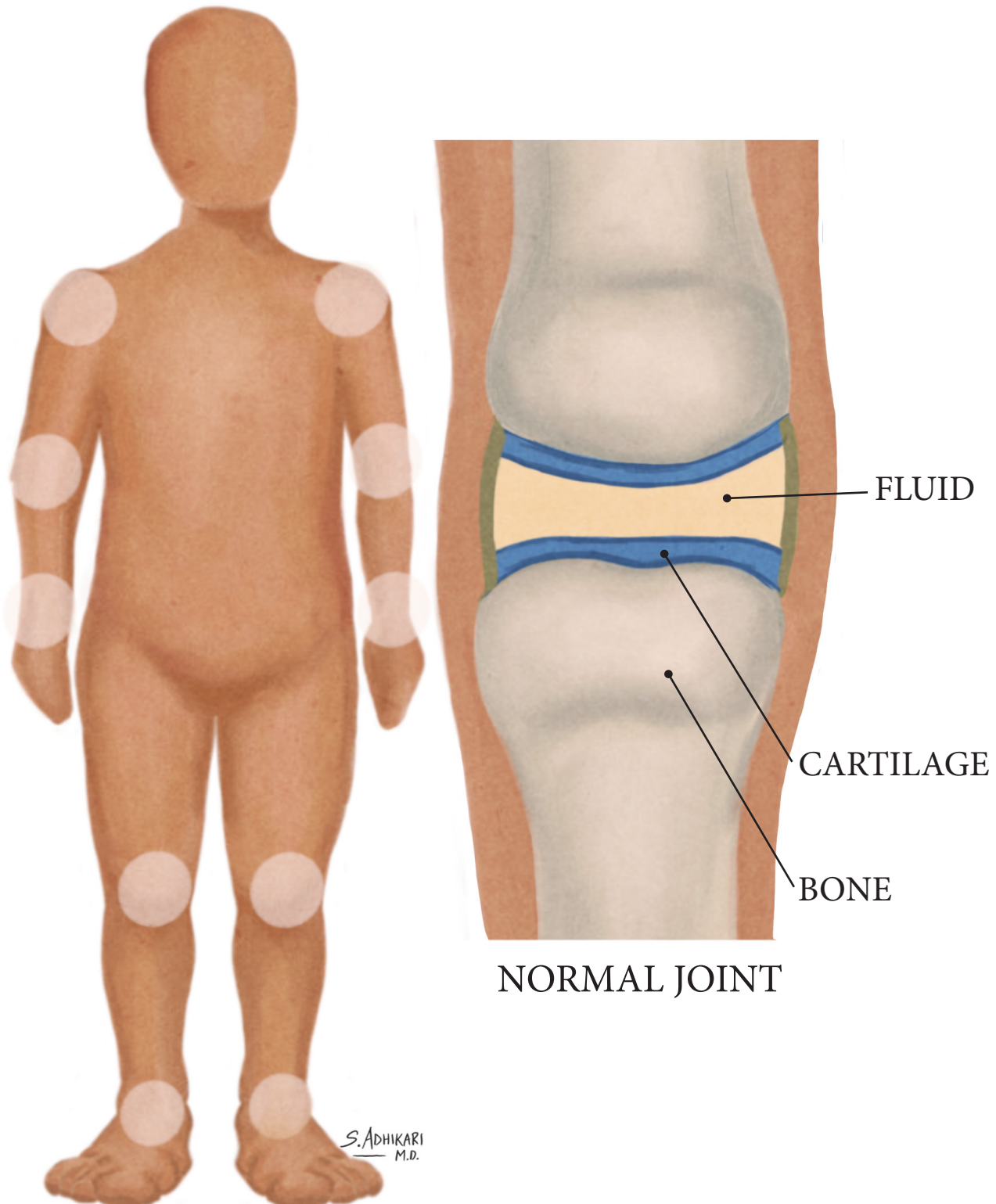
KNEE PAIN

FRACTURE vs SPRAIN



JOINT DISEASE

NORMAL ANATOMY

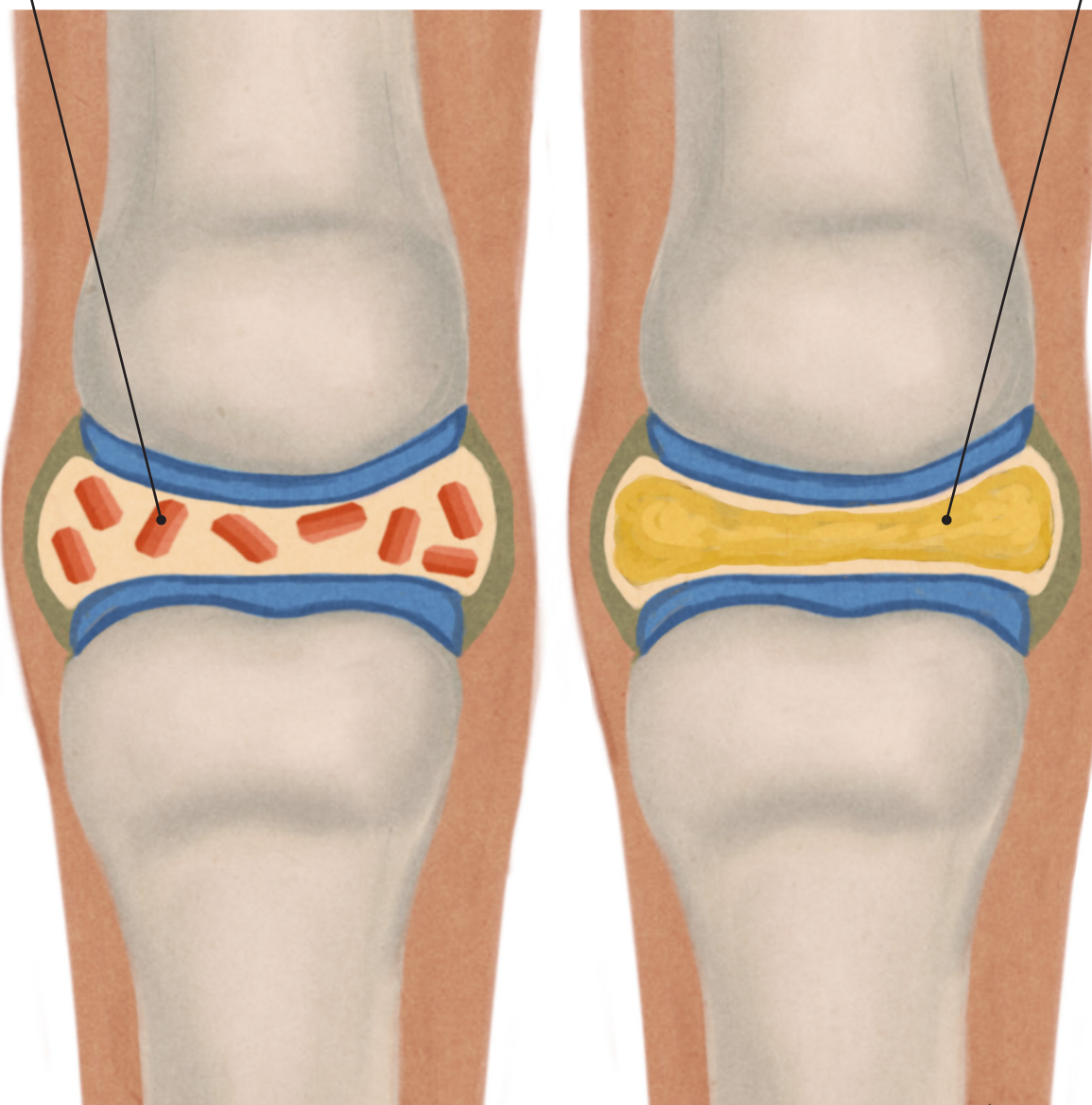

INFLAMED JOINT

GOUT vs SEPTIC JOINT

CRYSTALS

PUS

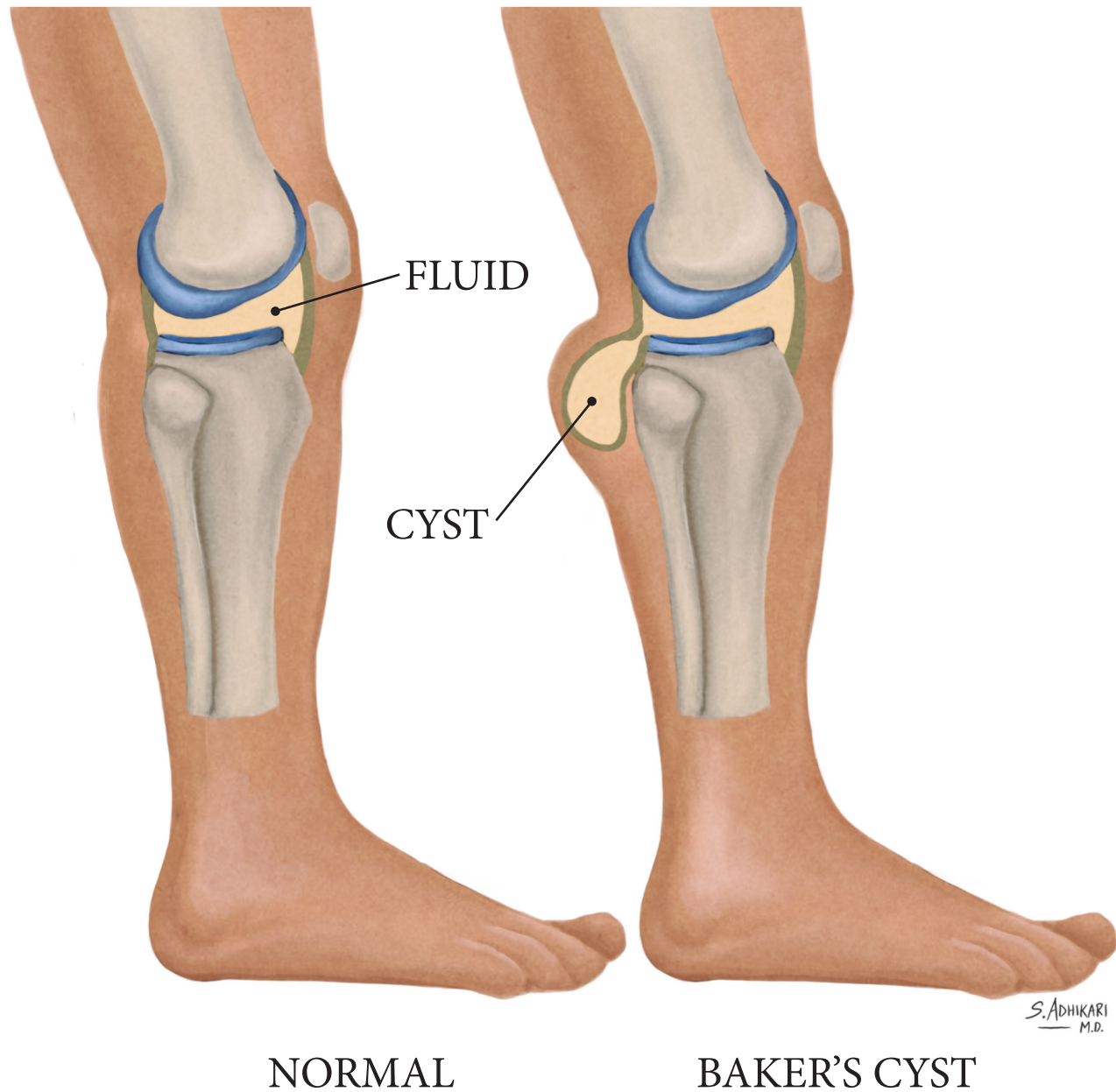


GOUT

SEPTIC JOINT

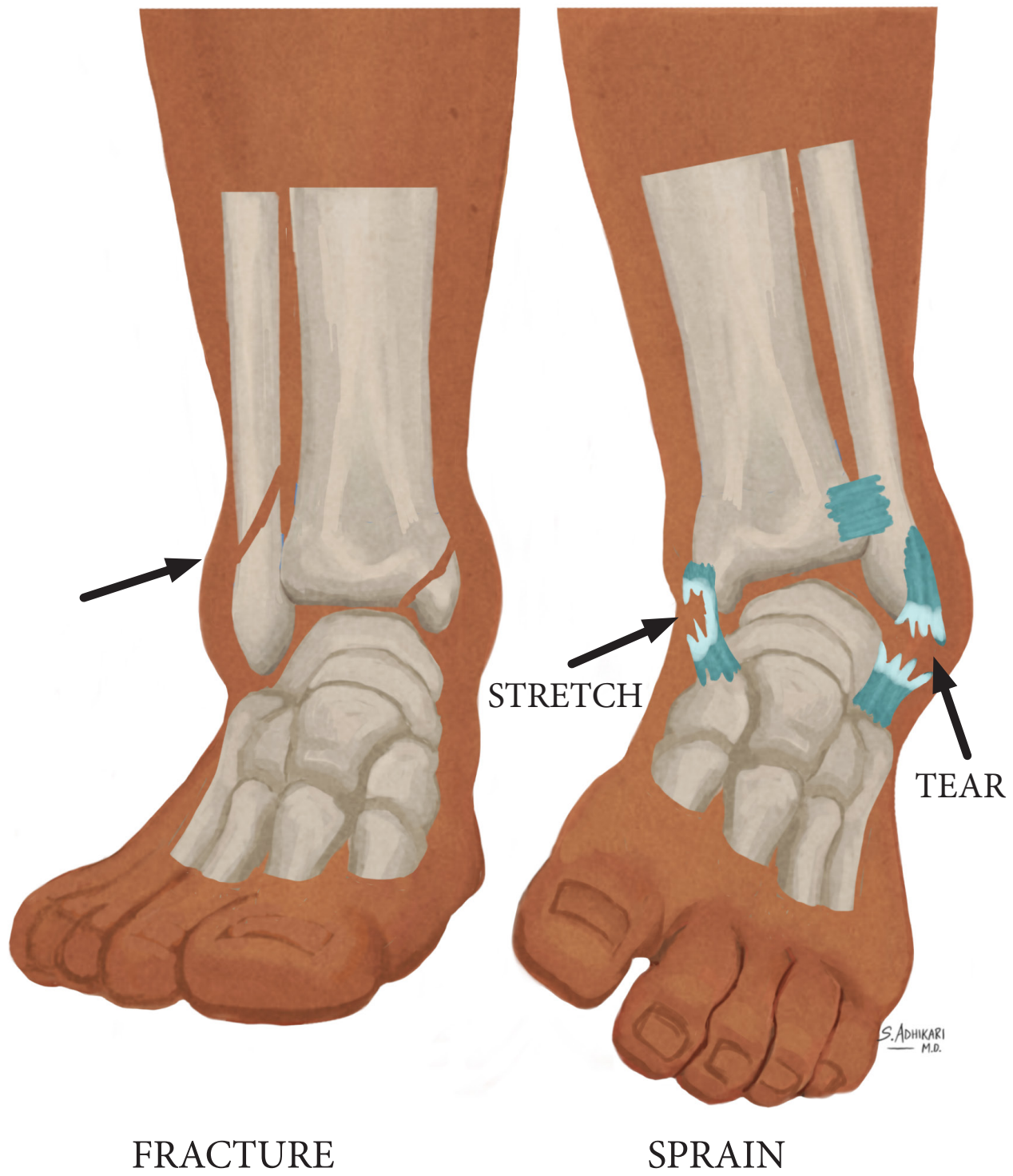
S. ADHIKARI
M.D.

BAKER'S CYST

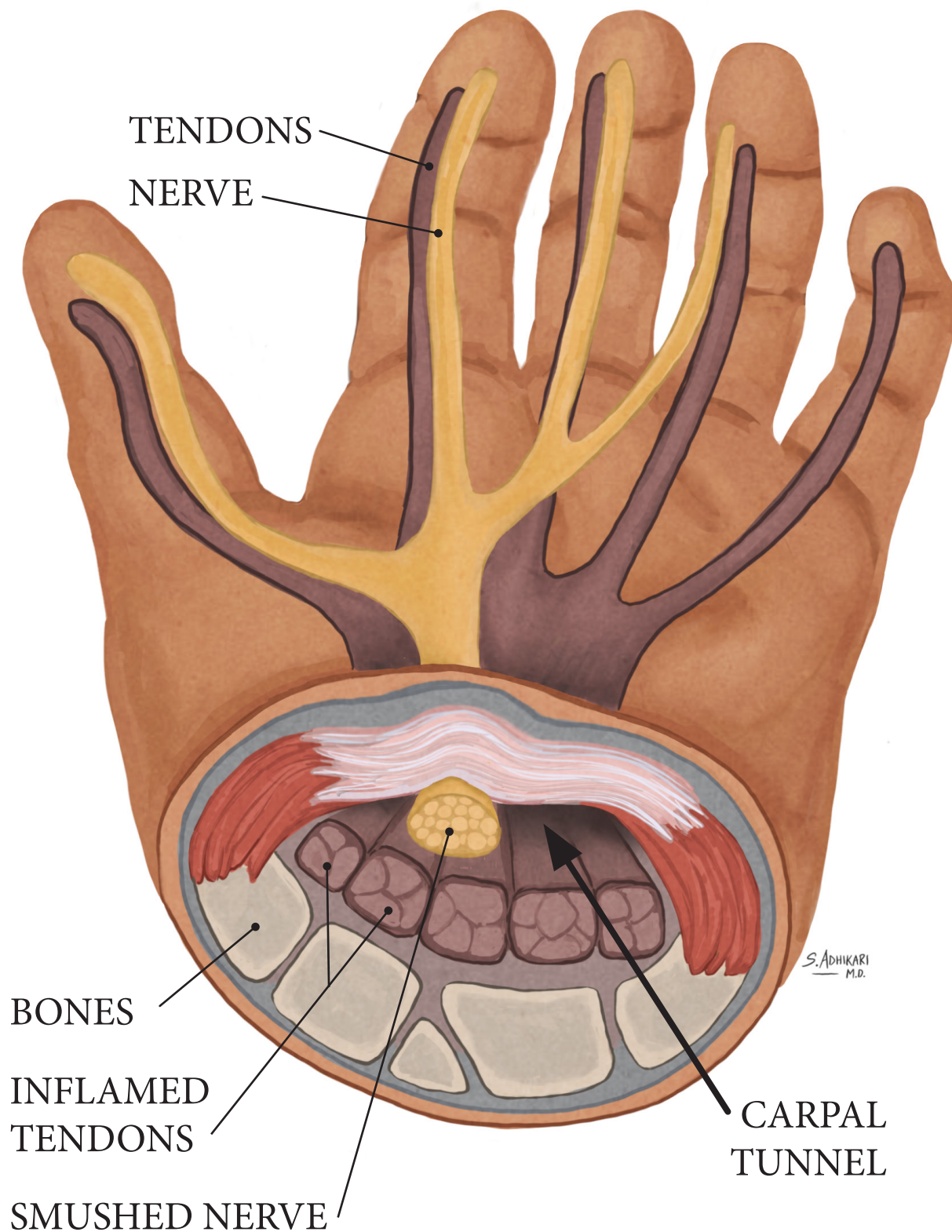


ANKLE PAIN

FRACTURE vs SPRAIN

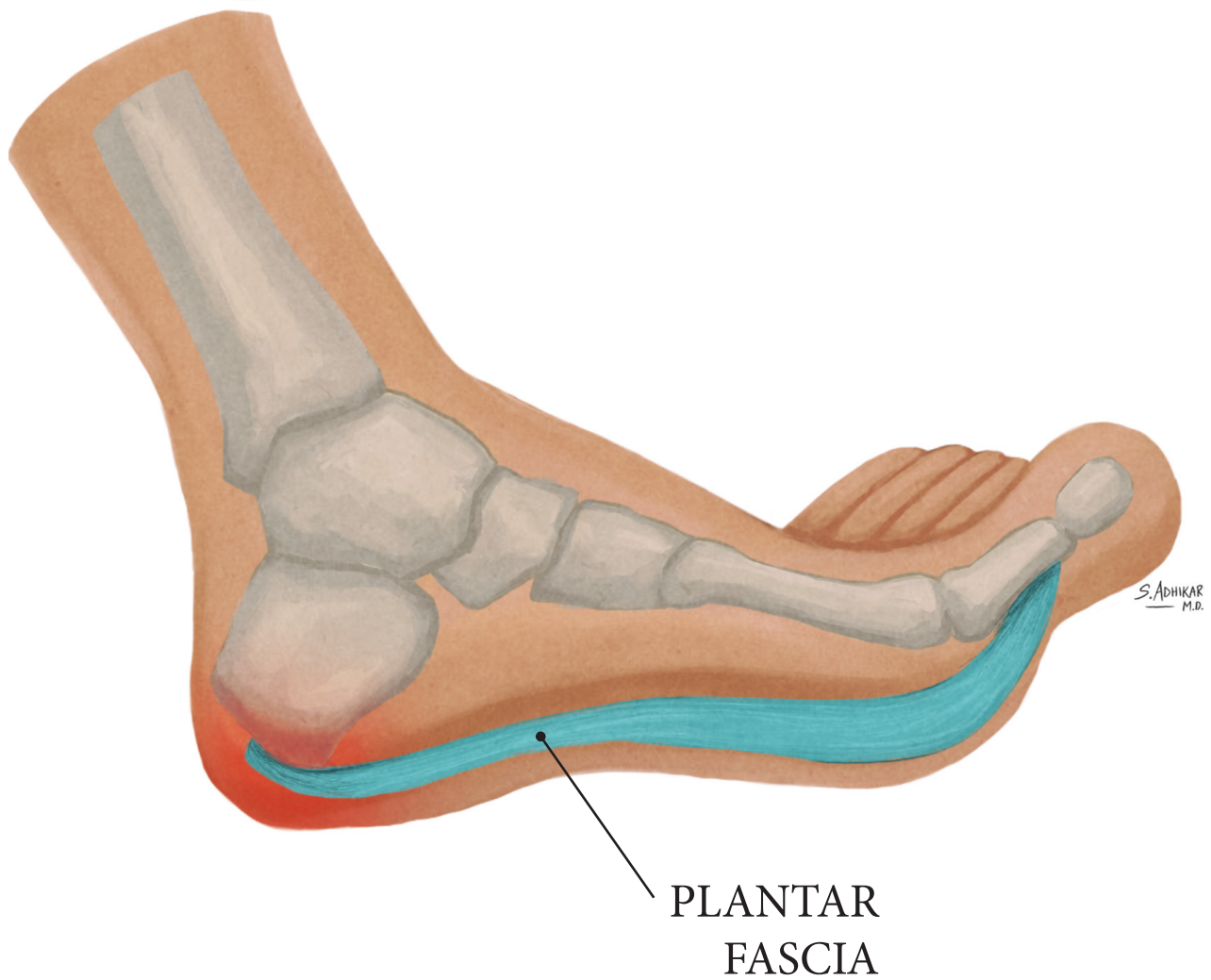


WRIST PAIN CARPAL TUNNEL SYNDROME



FOOT PAIN

PLANTAR FASCIITIS



BROKEN BACK COMPRESSION FRACTURE

