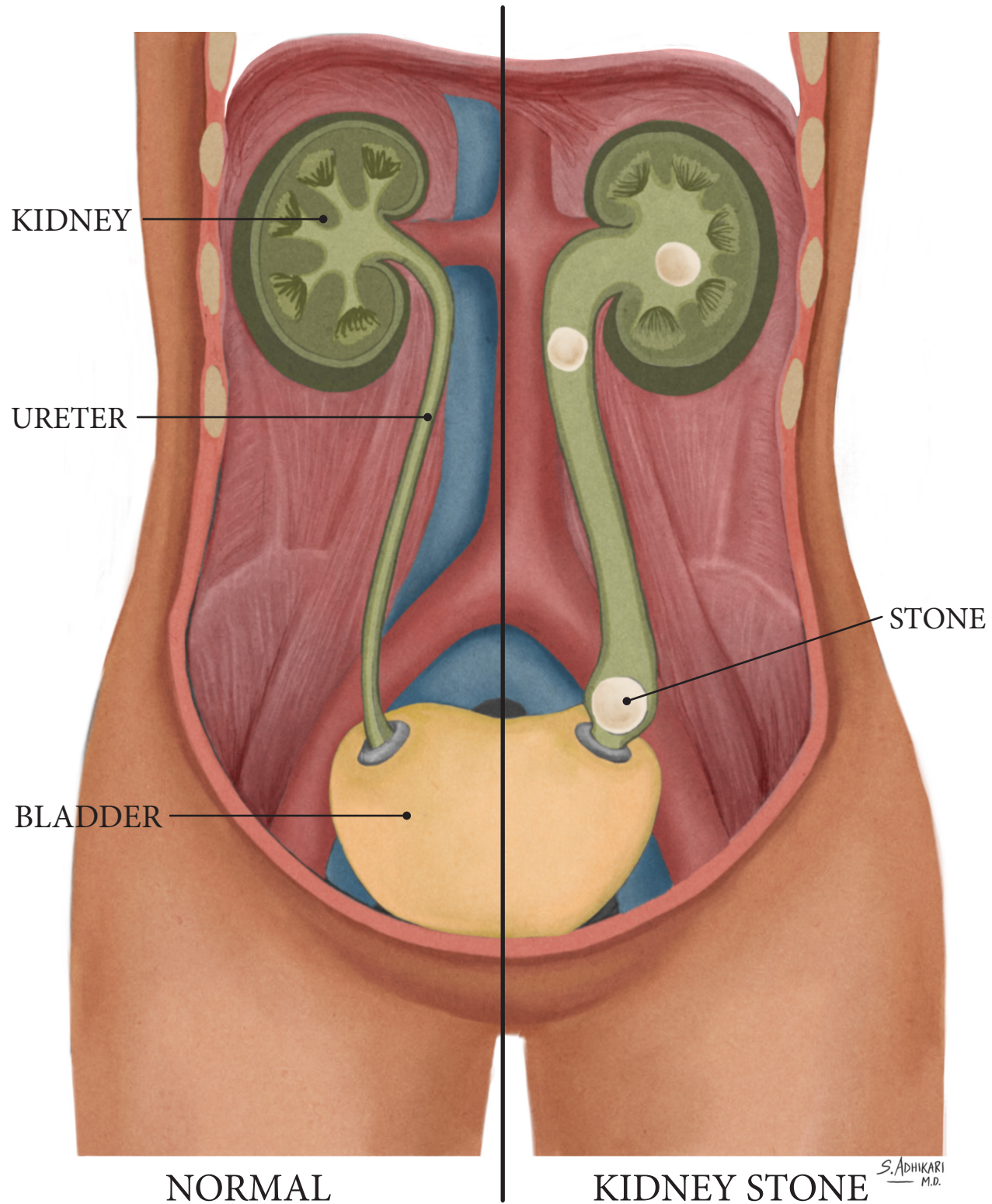


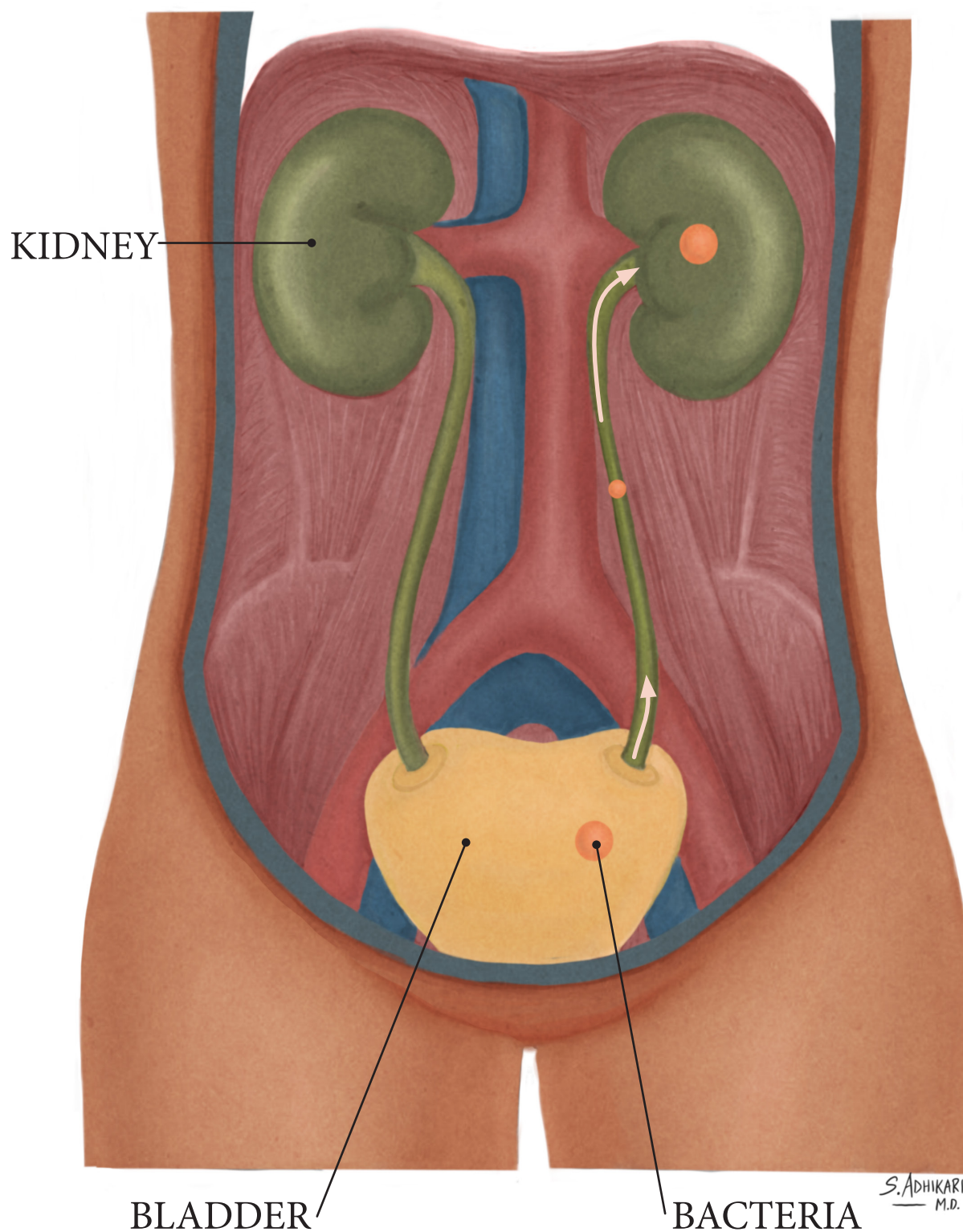
# KIDNEY STONE

## NEPHROLITHIASIS



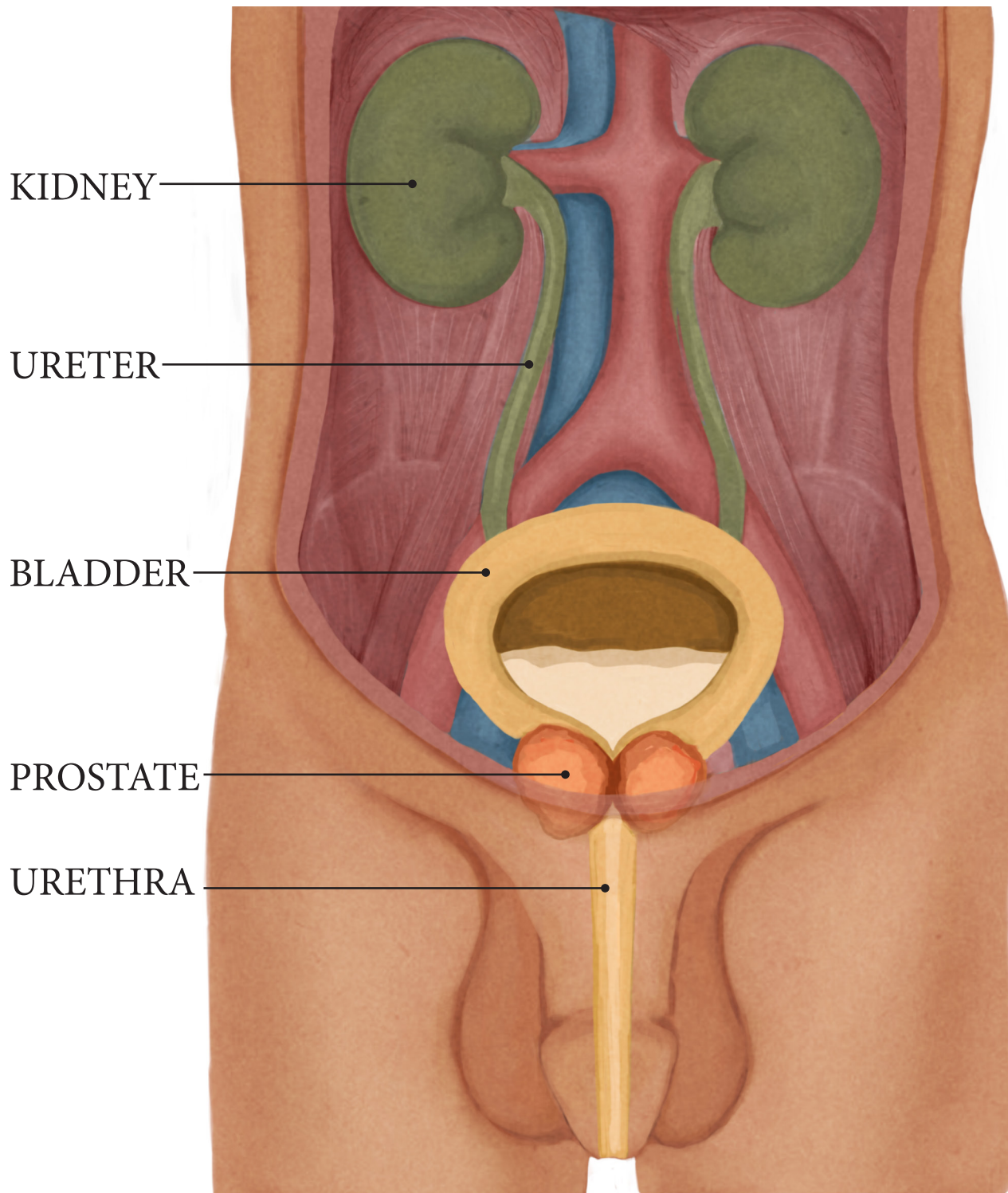
# URINARY TRACT INFECTION

## CYSTITIS vs PYELONEPHRITIS



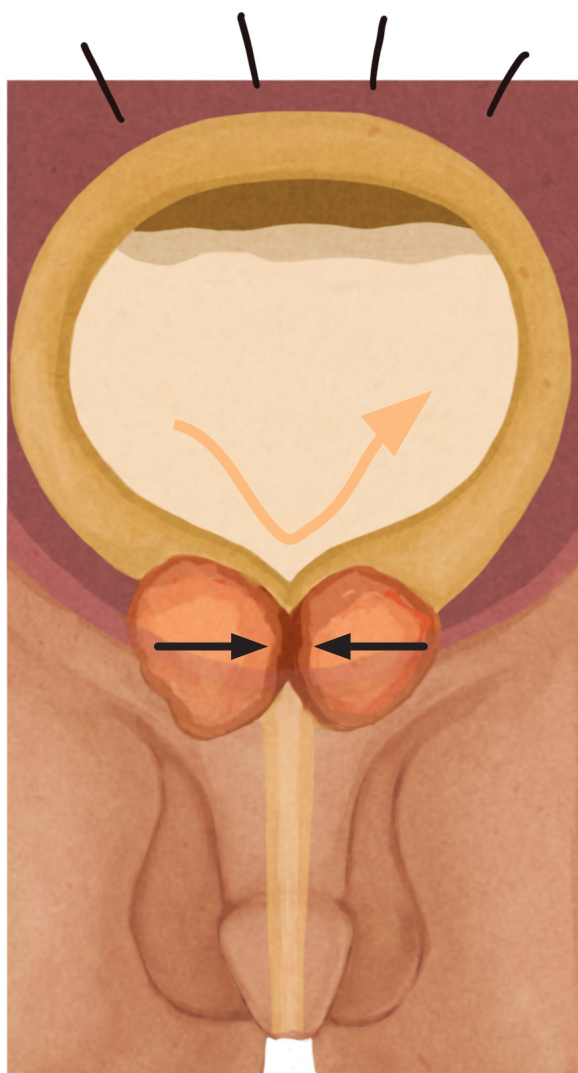


## ENLARGED PROSTATE BENIGN PROSTATIC HYPERTROPHY (BPH)

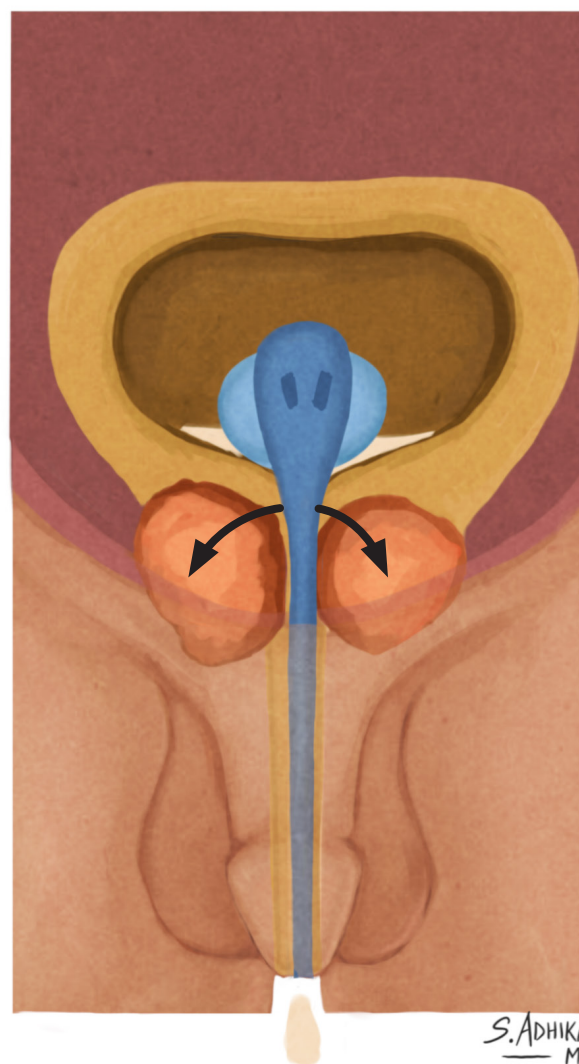


S. ADHIKARI  
M.D.

# URINARY RETENTION



PROSTATE BLOCKS  
URINE OUTFLOW

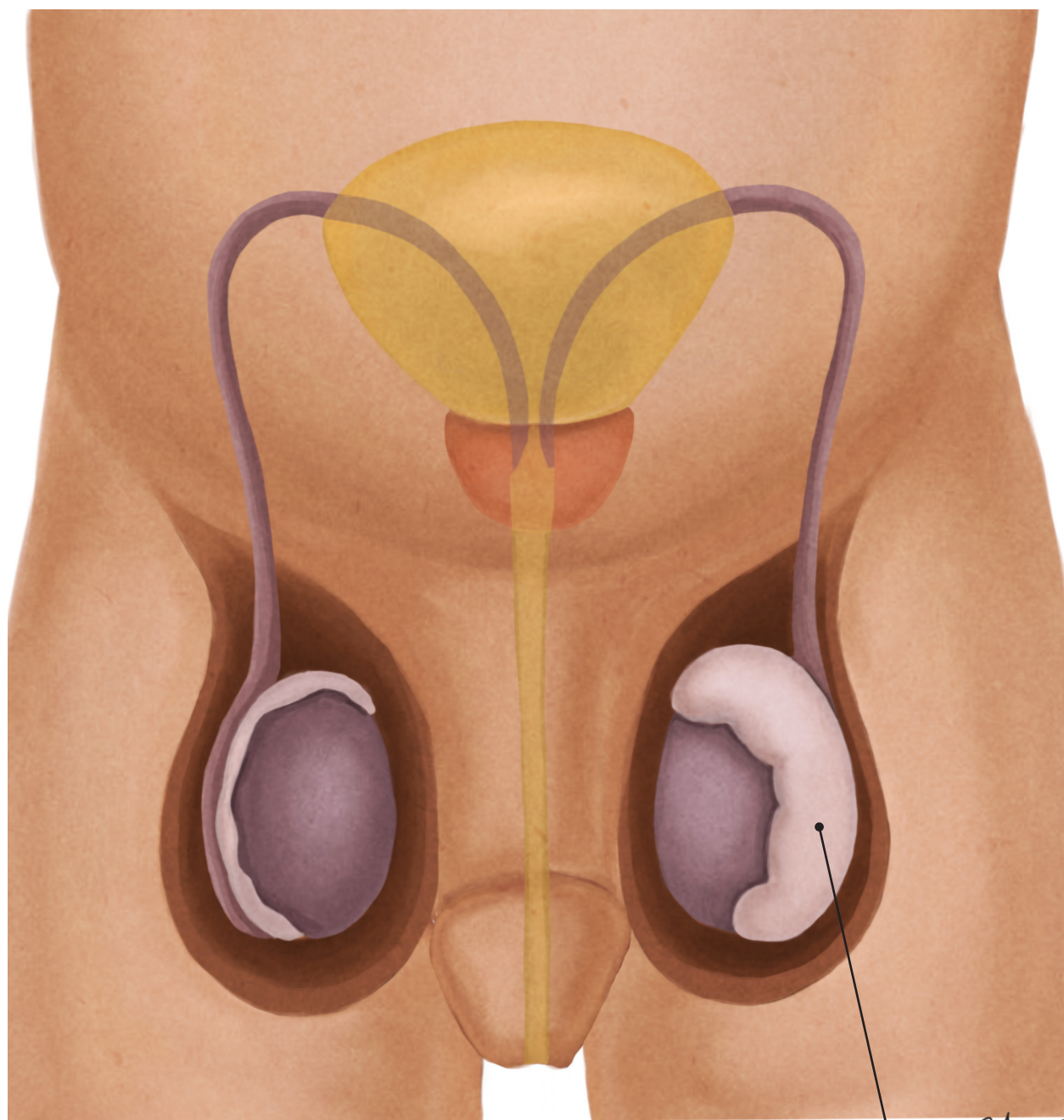


FOLEY CATHETER  
PUSHES PROSTATE  
ASIDE



# TESTICULAR SWELLING

## EPIDIDYMITIS



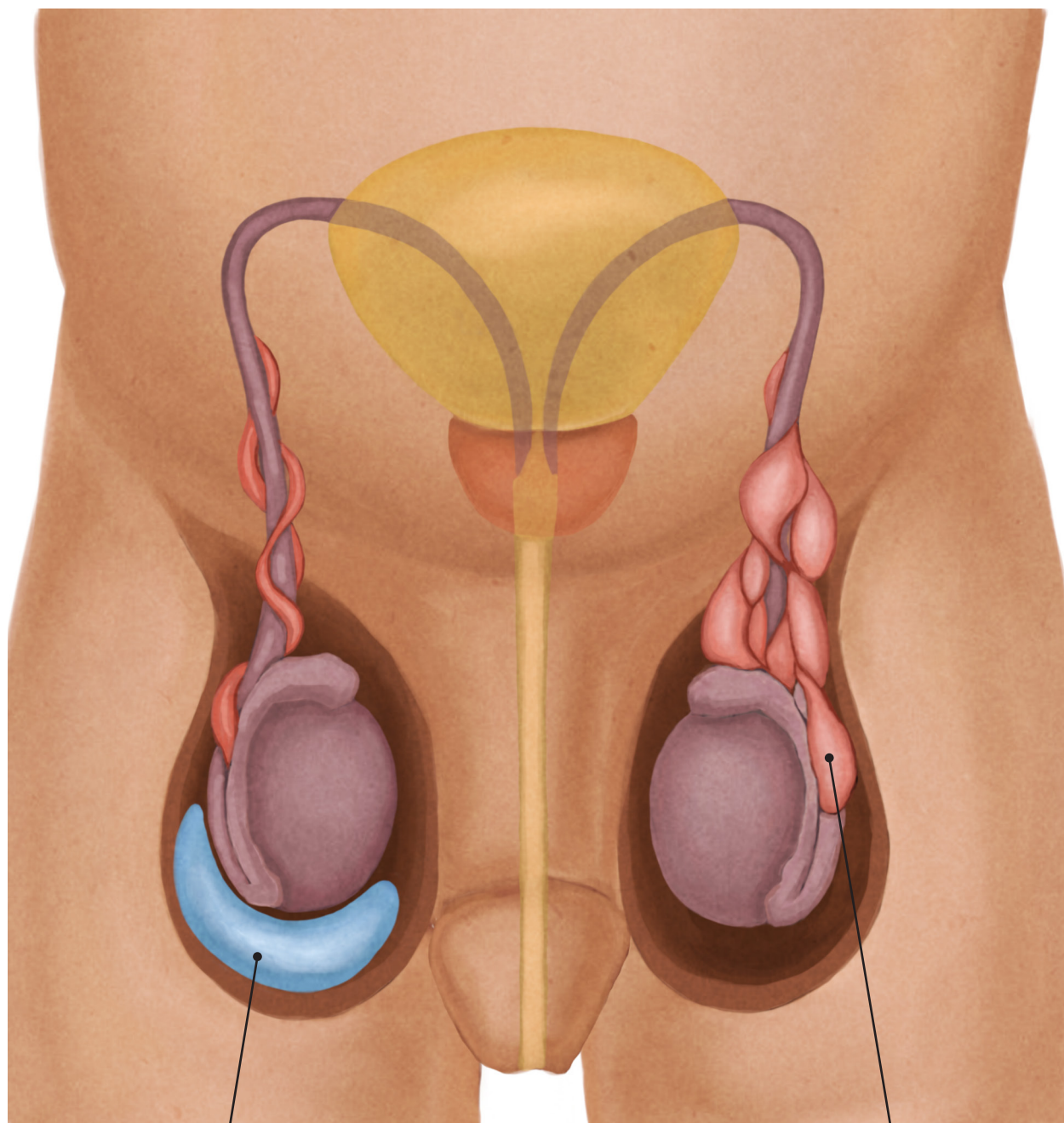
NORMAL

EPIDIDYMITIS

S. ADHIKARI  
M.D.

# TESTICULAR SWELLING

## HYDROCELE vs VARICOCELE



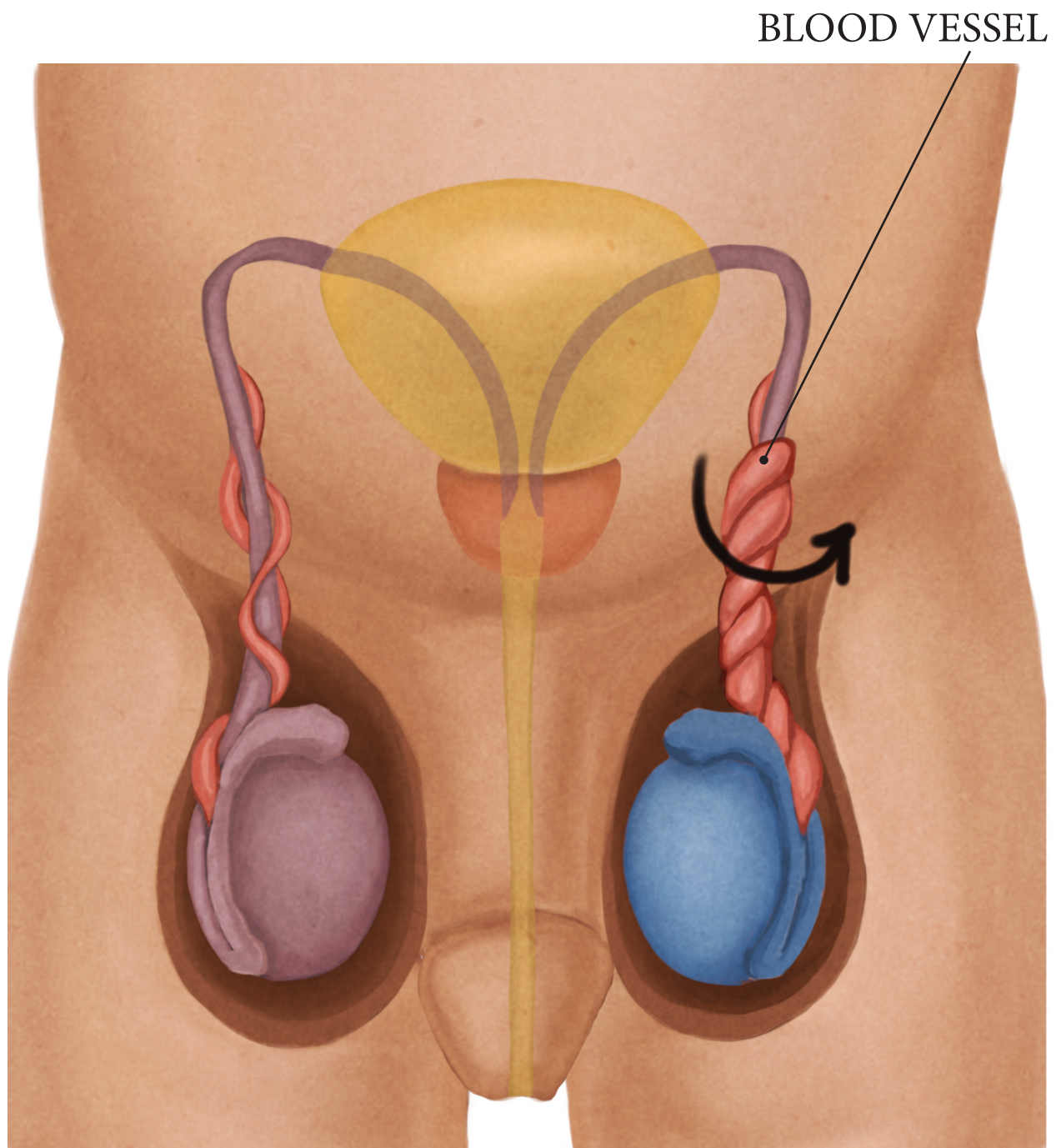
HYDROCELE

VARICOCELE

S. ADHIKARI  
M.D.



# TESTICULAR TORSION

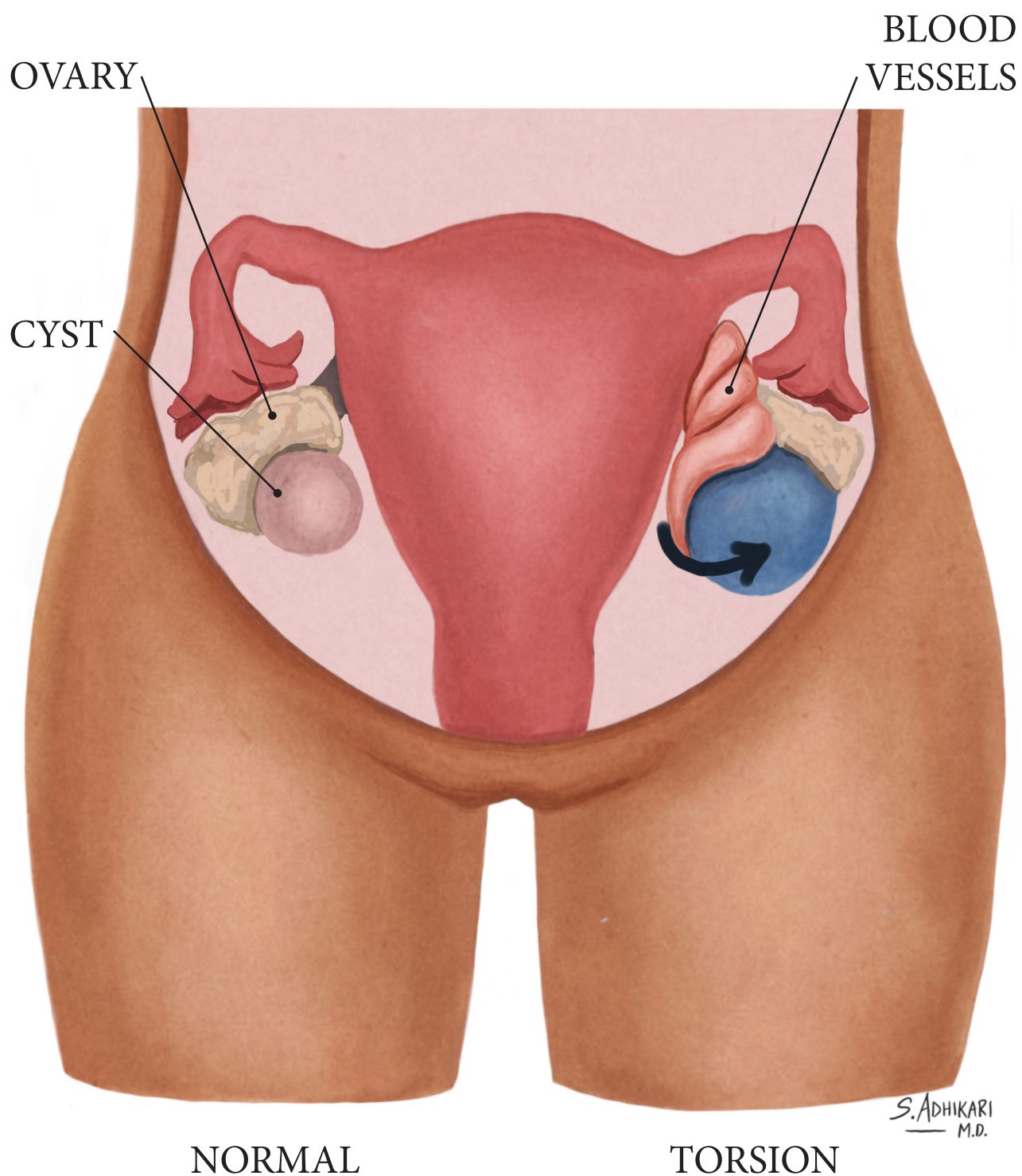


NORMAL

TORSION

S. ADHIKARI  
— M.D.

# OVARIAN TORSION



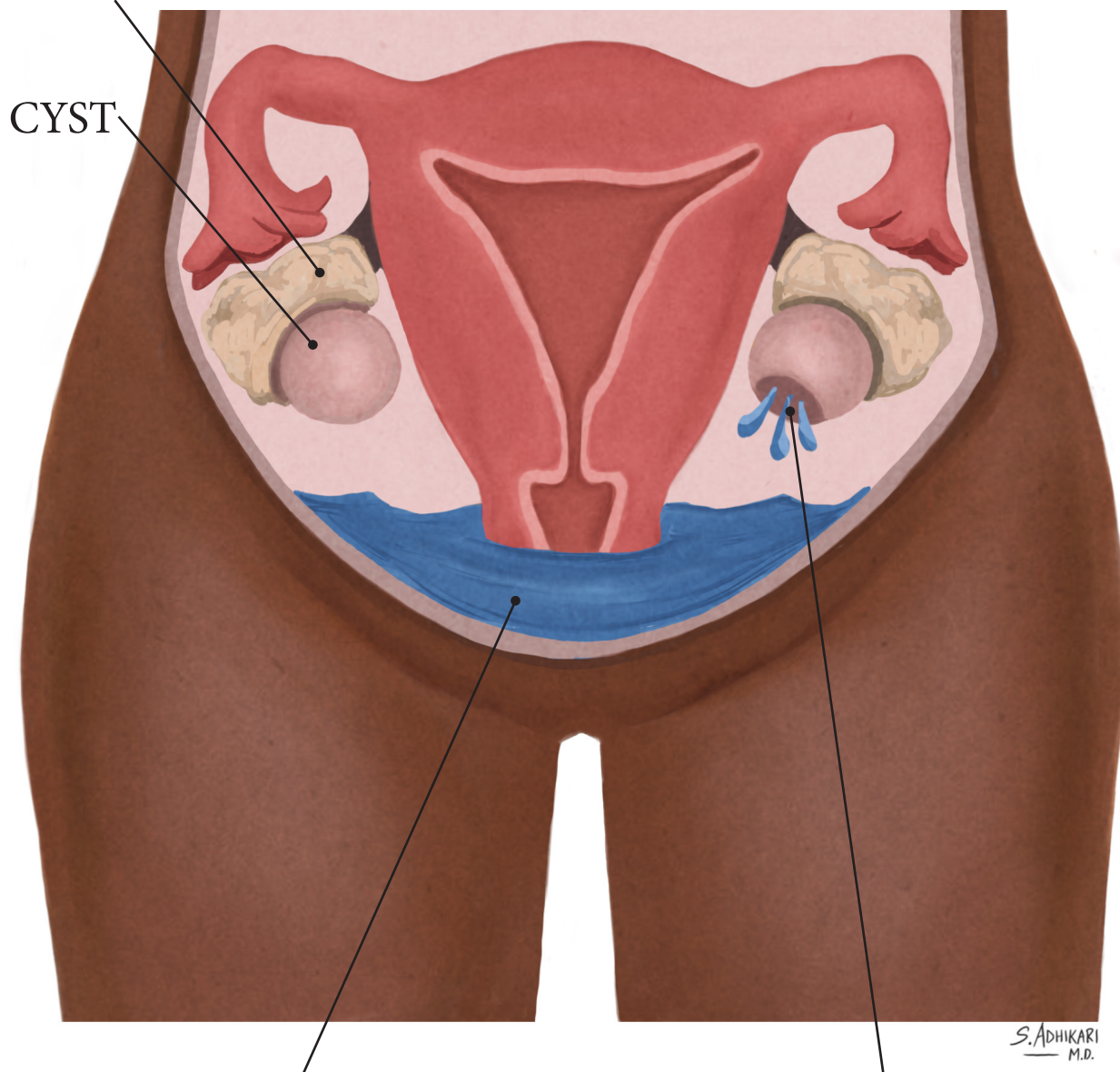


# OVARIAN CYST

## NORMAL CYST vs RUPTURED CYST

OVARY

CYST



FLUID SETTLES  
IN THE ABDOMINAL  
CAVITY

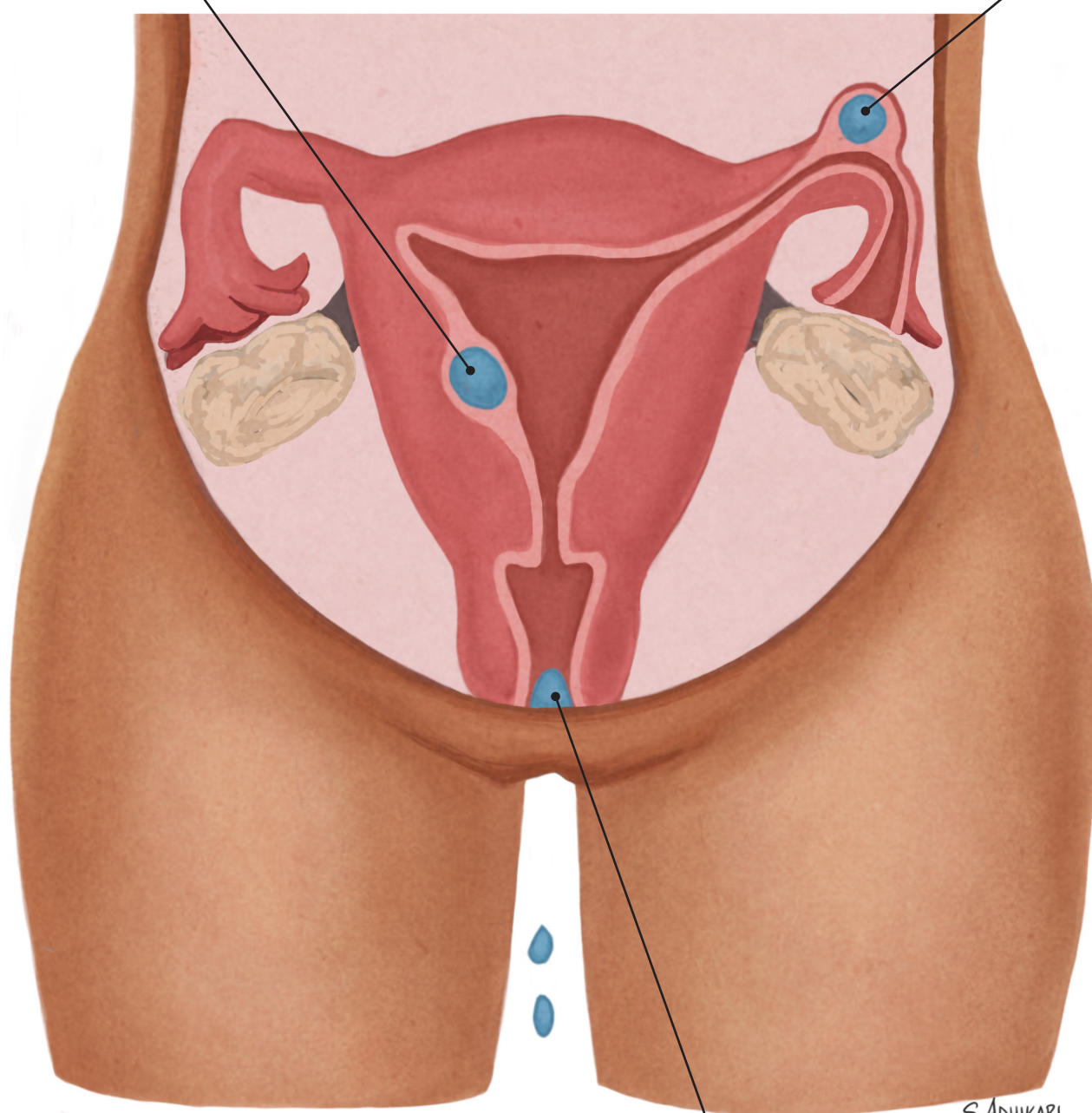
RUPTURED  
OVARIAN CYST

# EARLY PREGNANCY

## ABDOMINAL PAIN &/OR VAGINAL BLEEDING

NORMAL  
PREGNANCY

ECTOPIC  
PREGNANCY



MISCARRIAGE

S. ADHIKARI  
M.D.

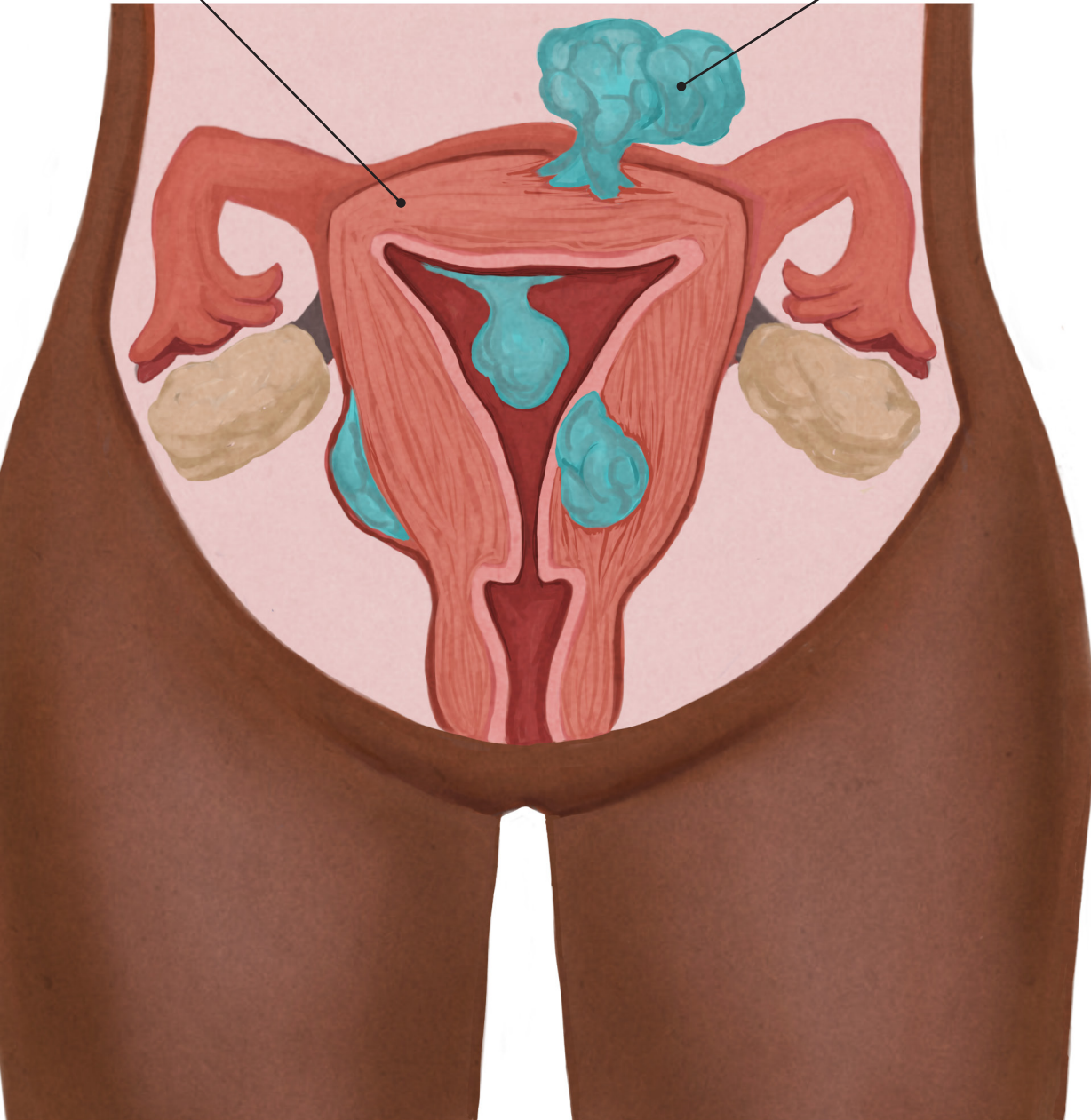


# FIBROIDS

## LEIOMYOMA

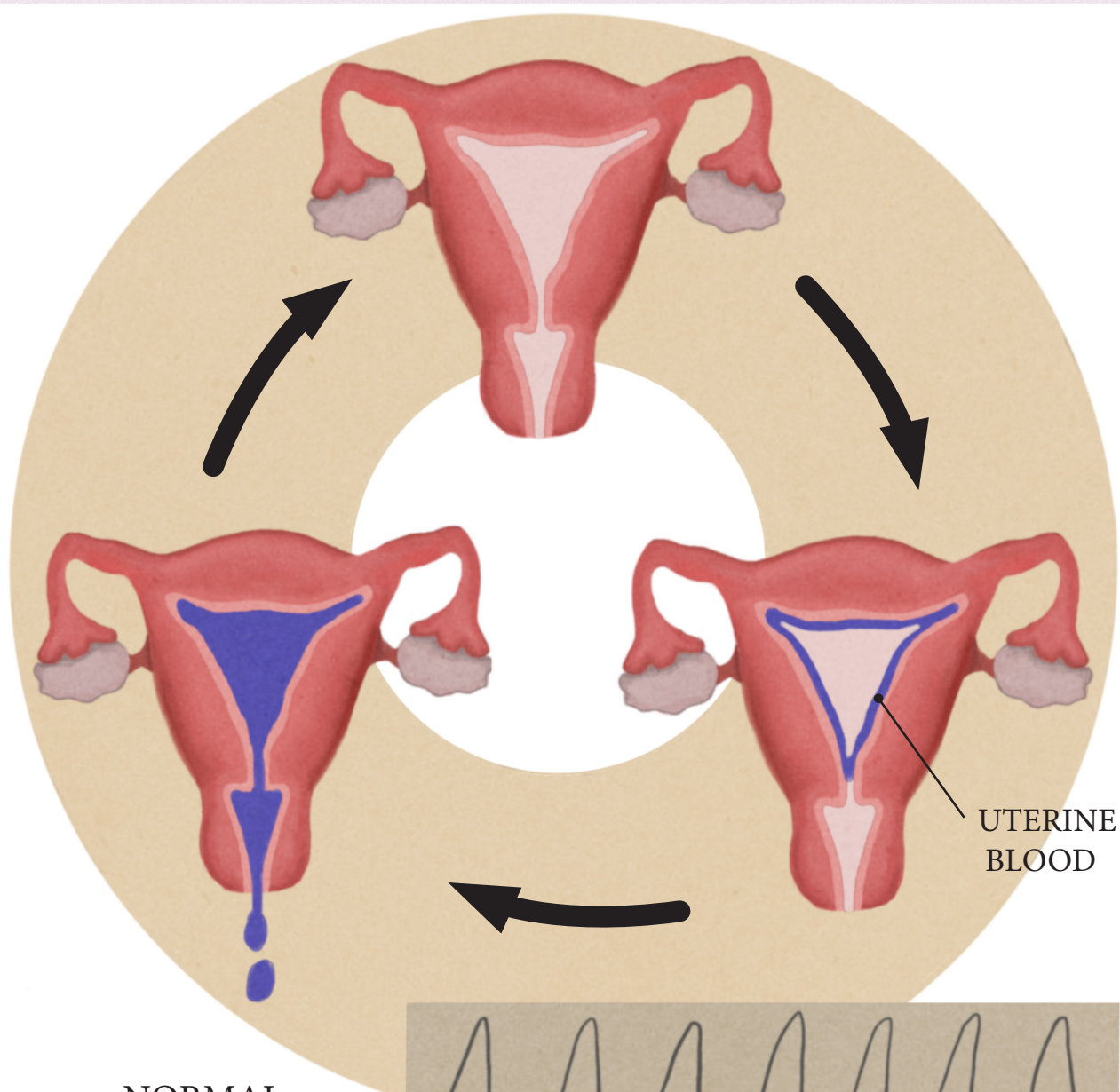
UTERUS

FIBROIDS



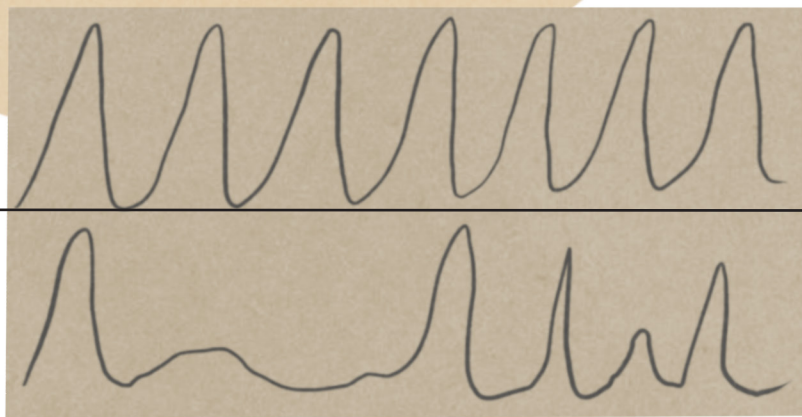
# IRREGULAR PERIODS

## ABNORMAL UTERINE BLEEDING



NORMAL  
HORMONAL CYCLE

HORMONAL  
FLUCTUATION  
IN IRREGULAR  
PERIODS

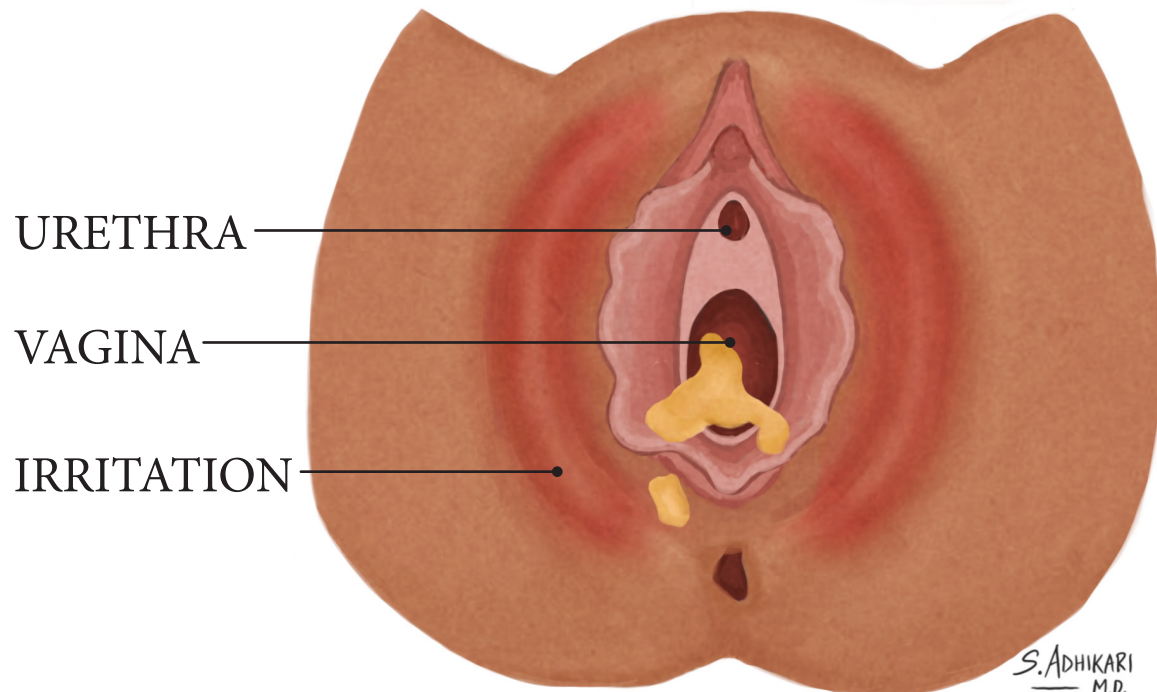
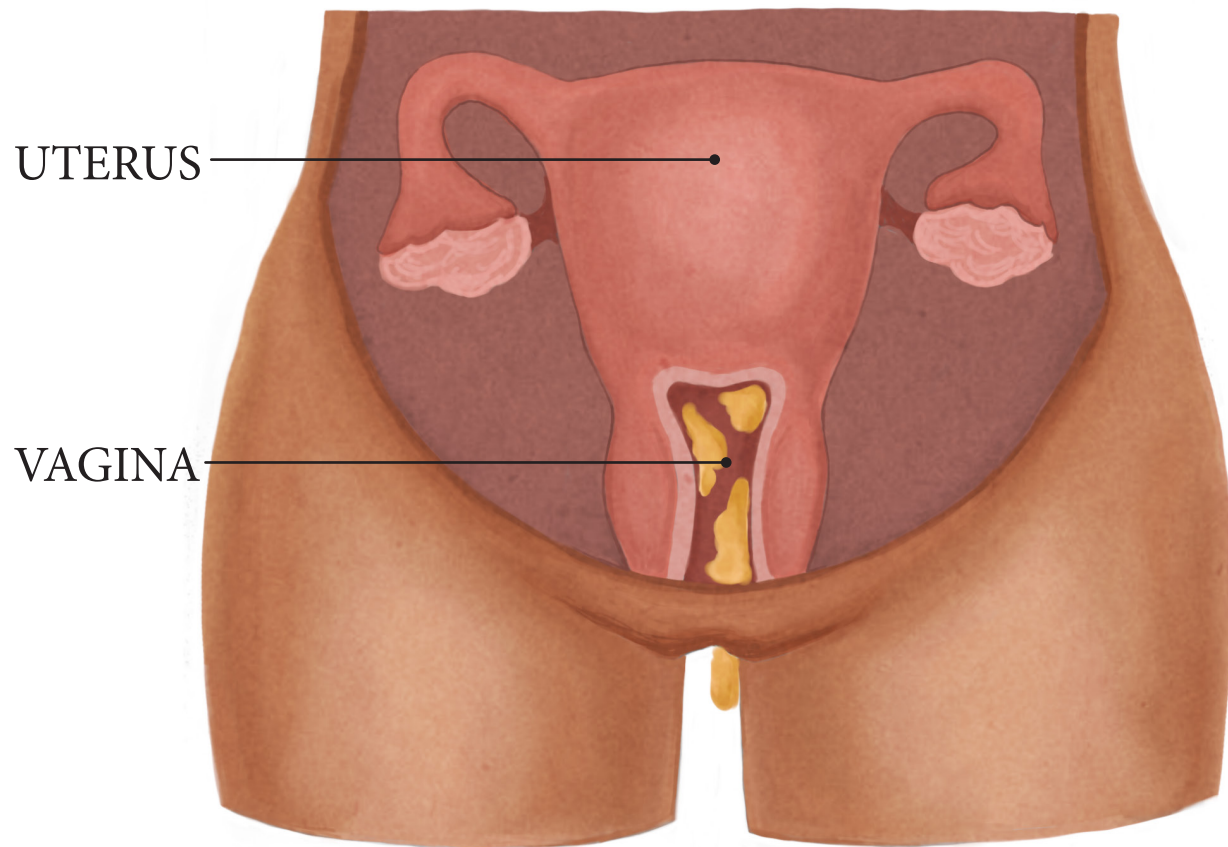


S. ADHIKARI  
M.D.



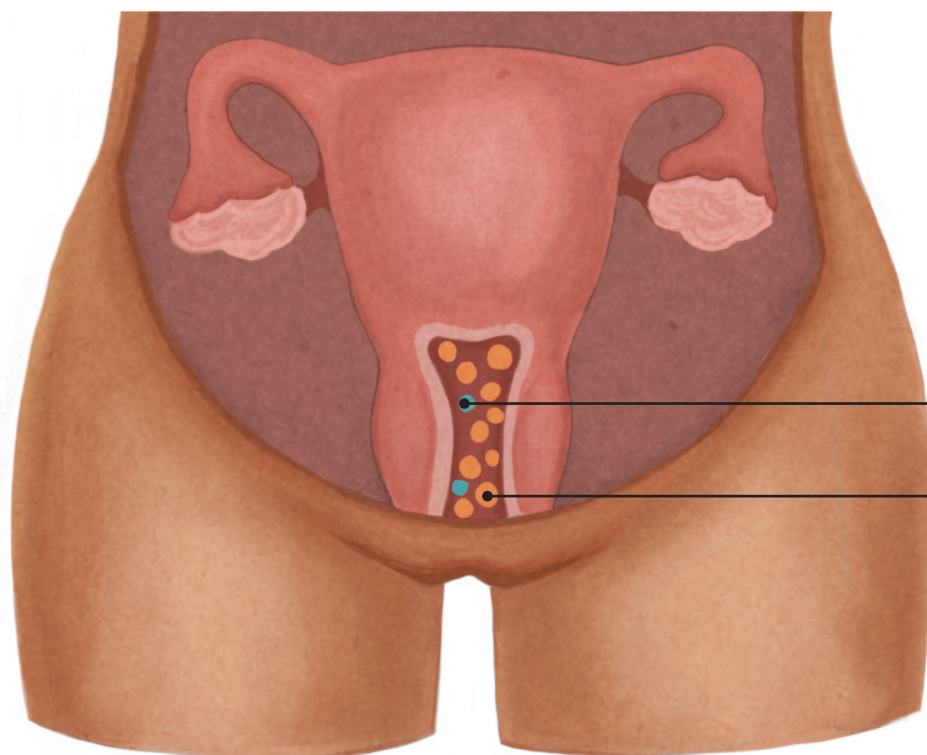
# YEAST INFECTION

## VAGINAL CANDIDIASIS



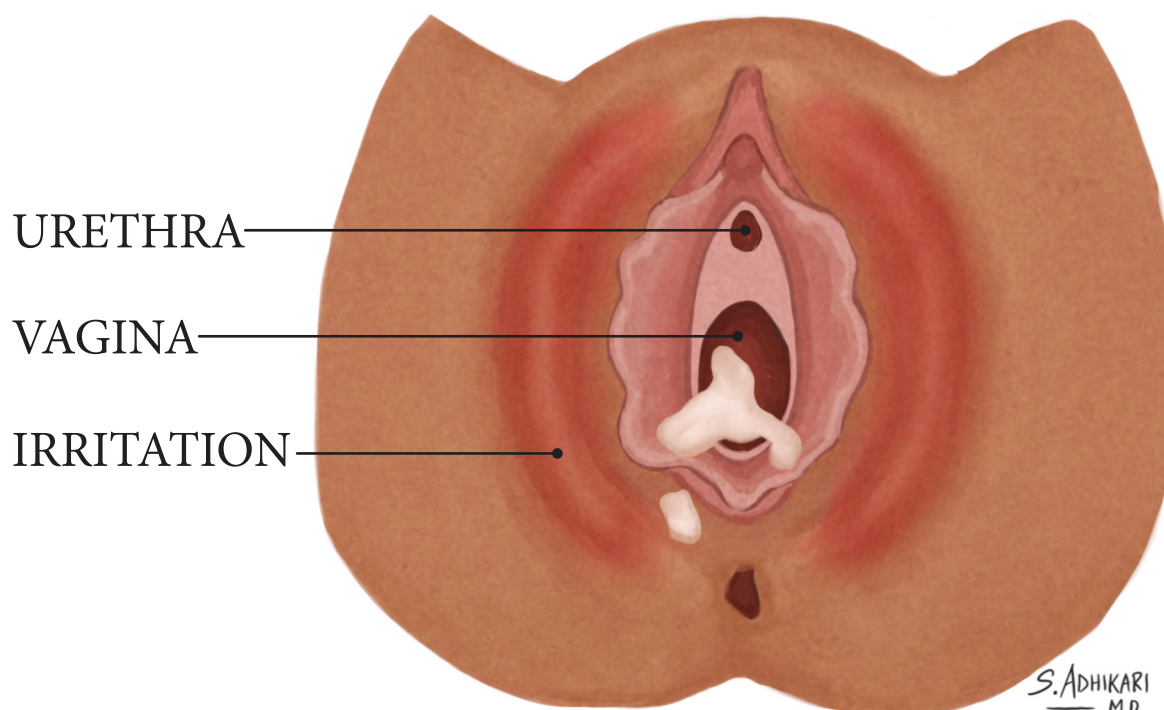
# VAGINAL DISCHARGE

## BACTERIAL VAGINOSIS



GOOD  
BACTERIA

BAD  
BACTERIA



URETHRA

VAGINA

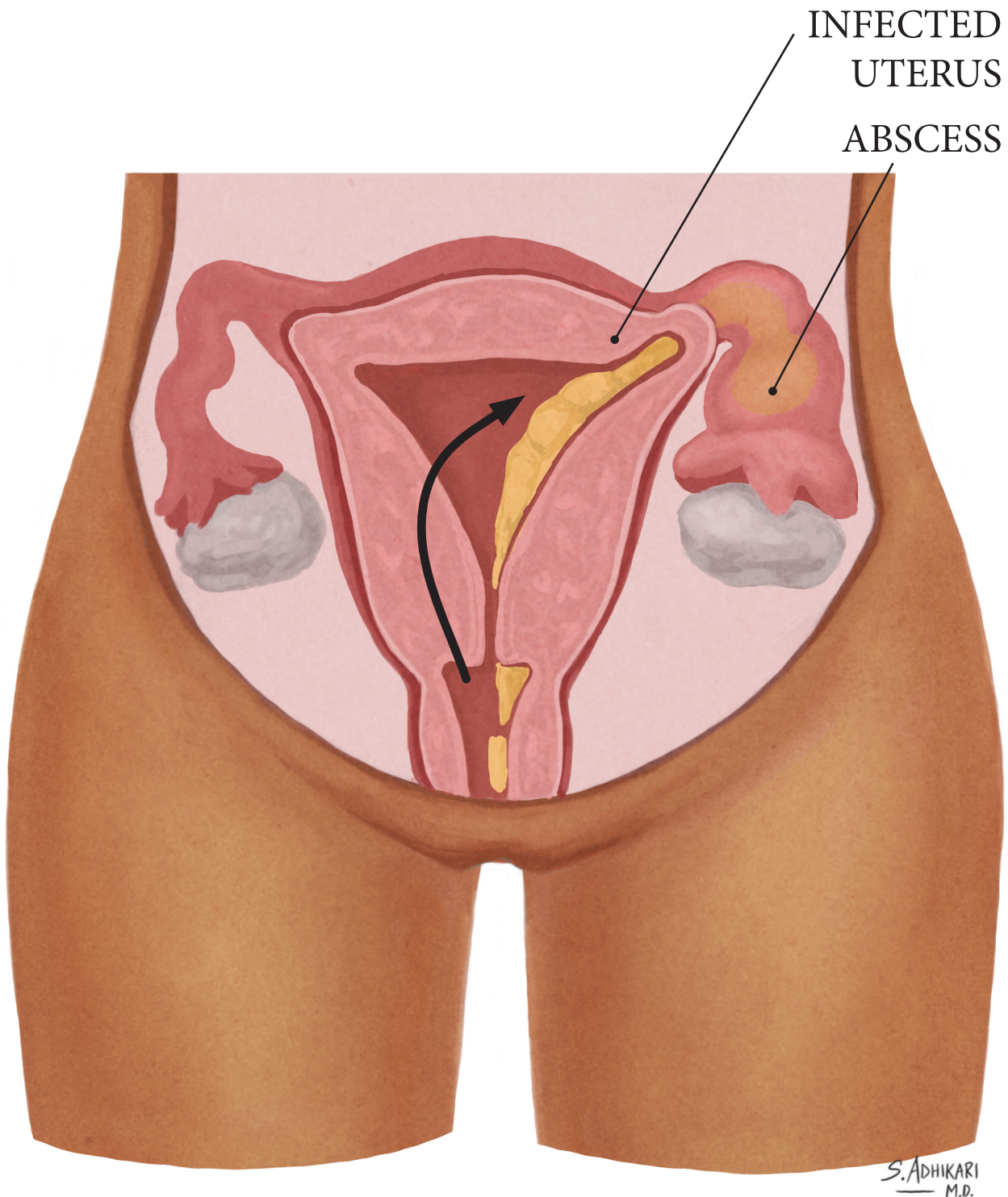
IRRITATION

S. ADHIKARI  
M.D.



# PELVIC INFECTION

PELVIC INFLAMMATORY DISEASE (PID) &  
TUBO-OVARIAN ABSCESS (TOA)

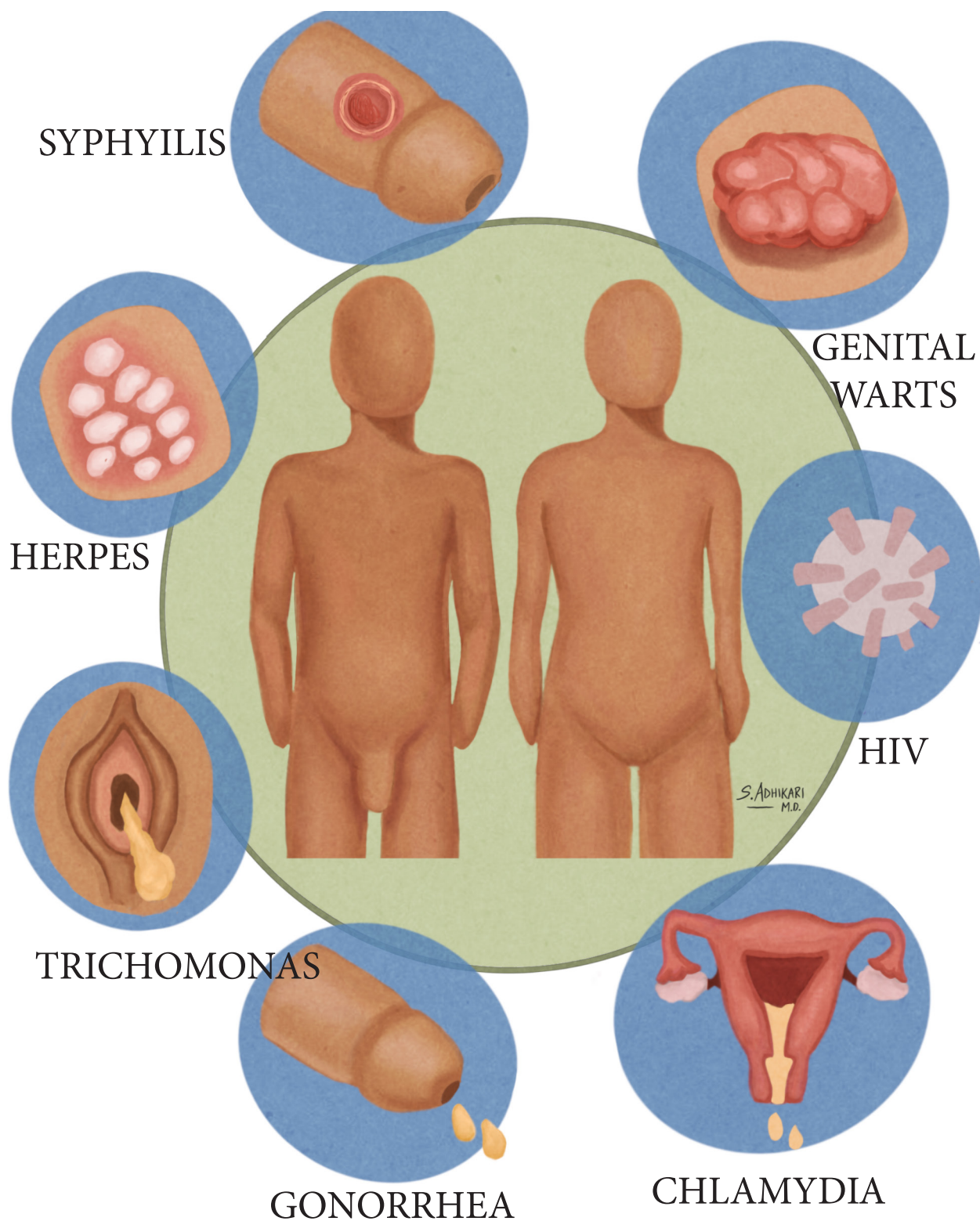


NORMAL

PELVIC INFECTION

S. ADHIKARI  
M.D.

# SEXUALLY TRANSMITTED INFECTION

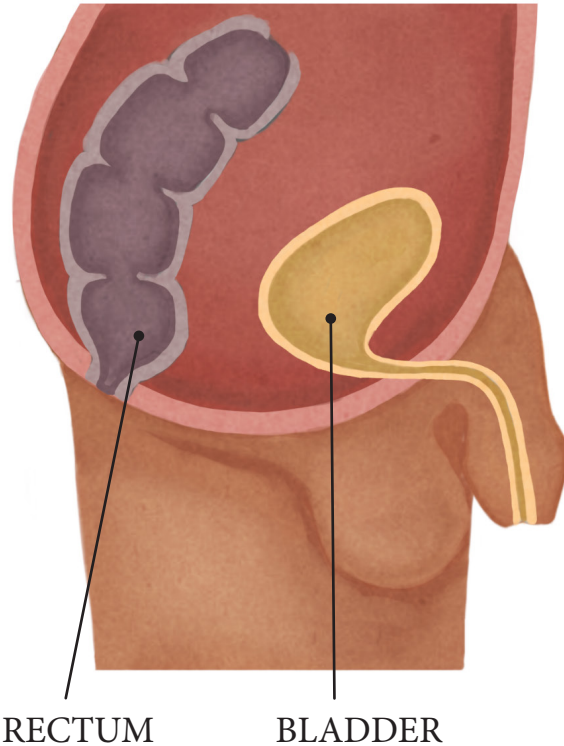




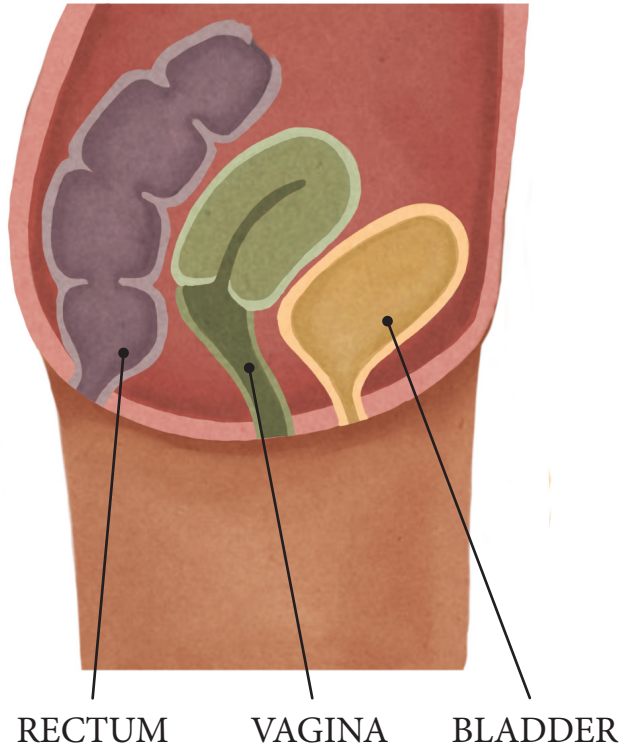
# LOWER ABDOMEN

MALE vs FEMALE

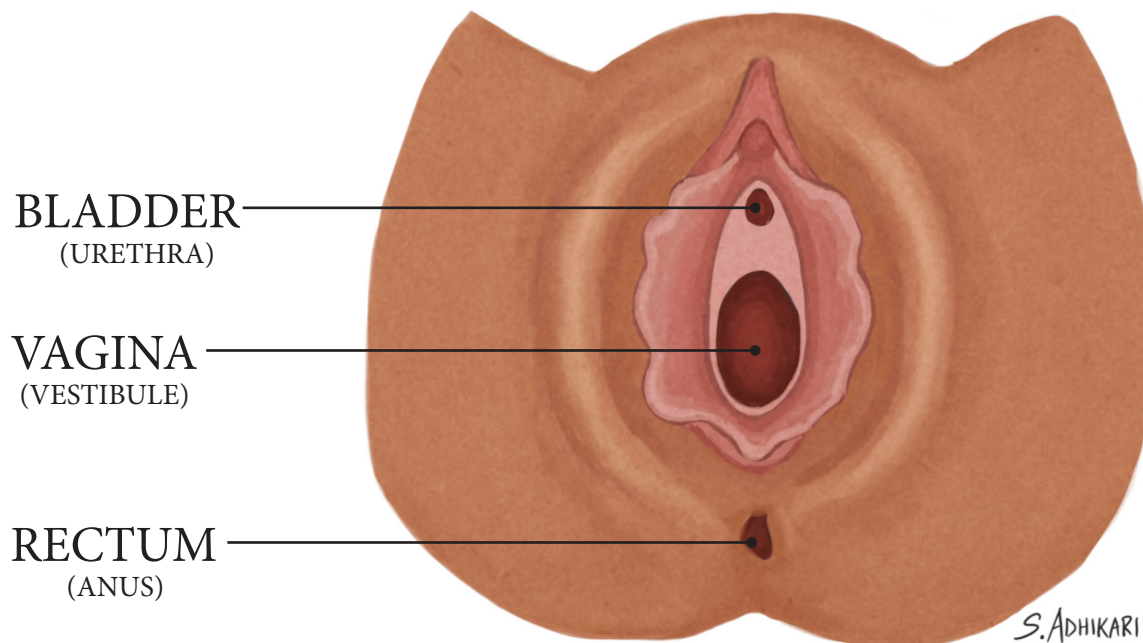
MALE



FEMALE



FEMALE



S. ADHIKARI  
M.D.