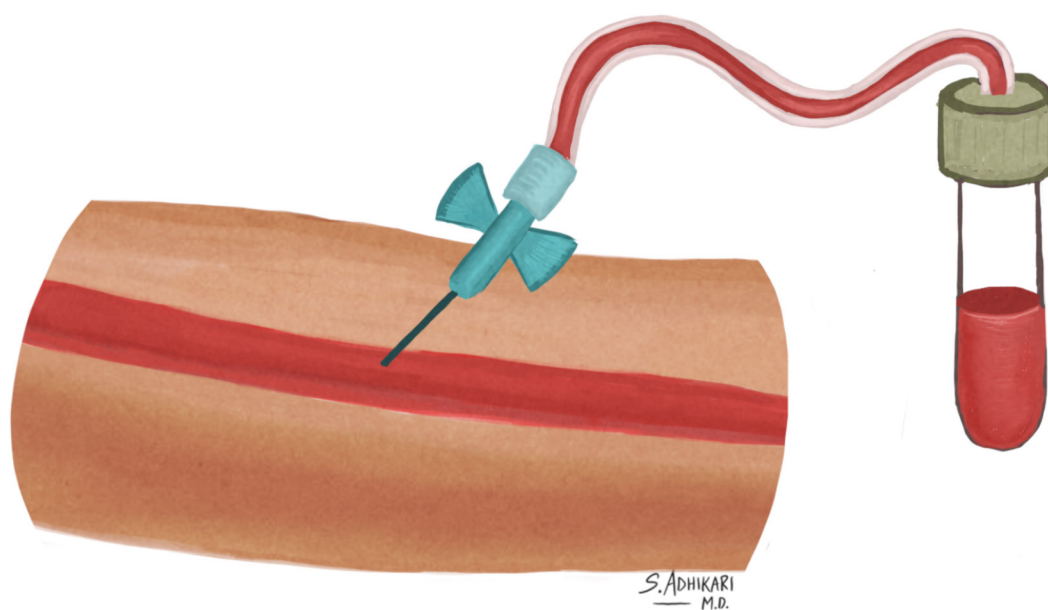
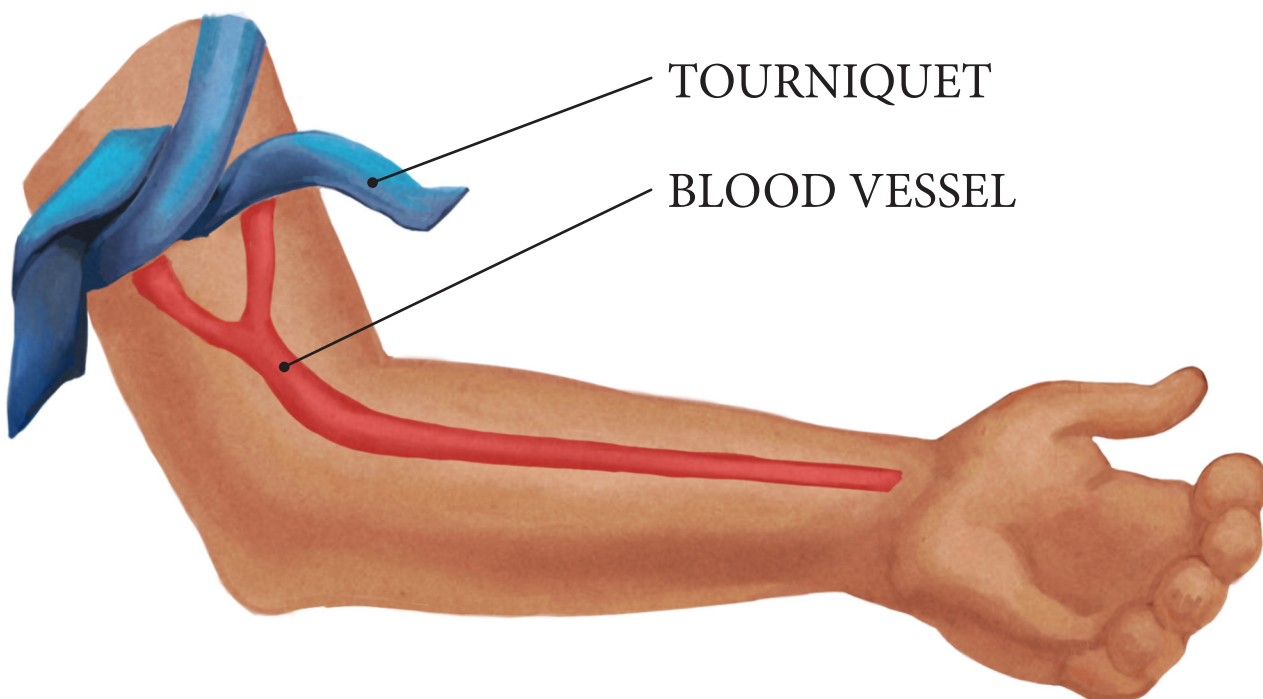
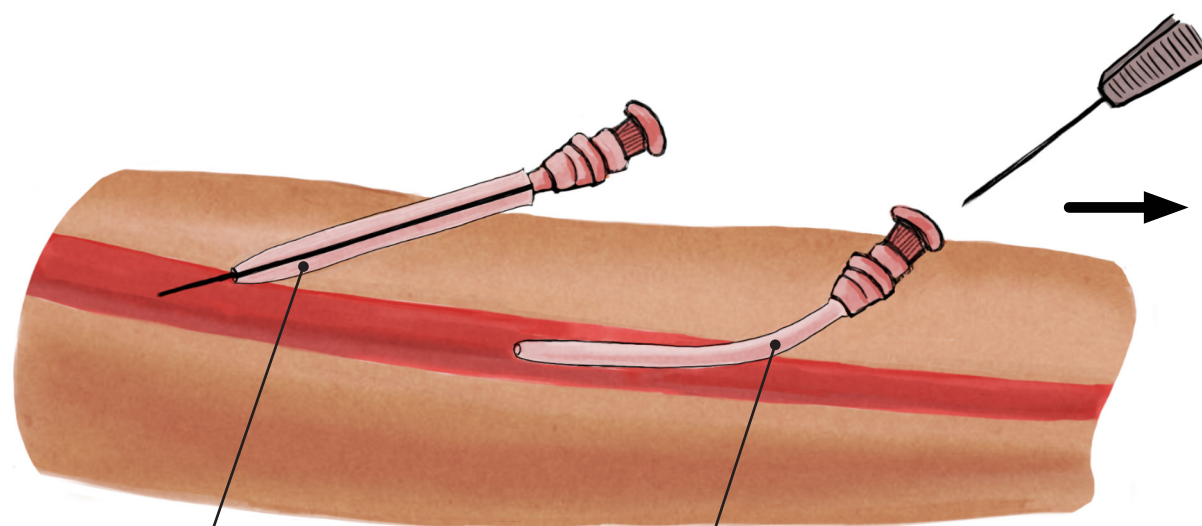
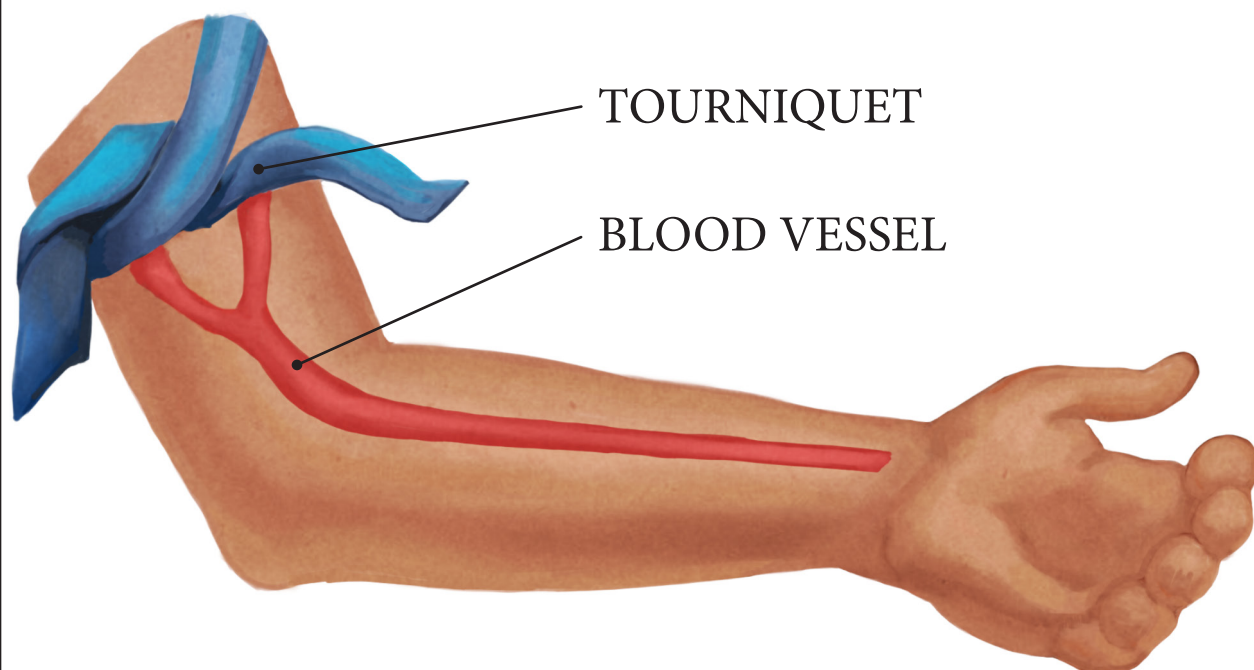


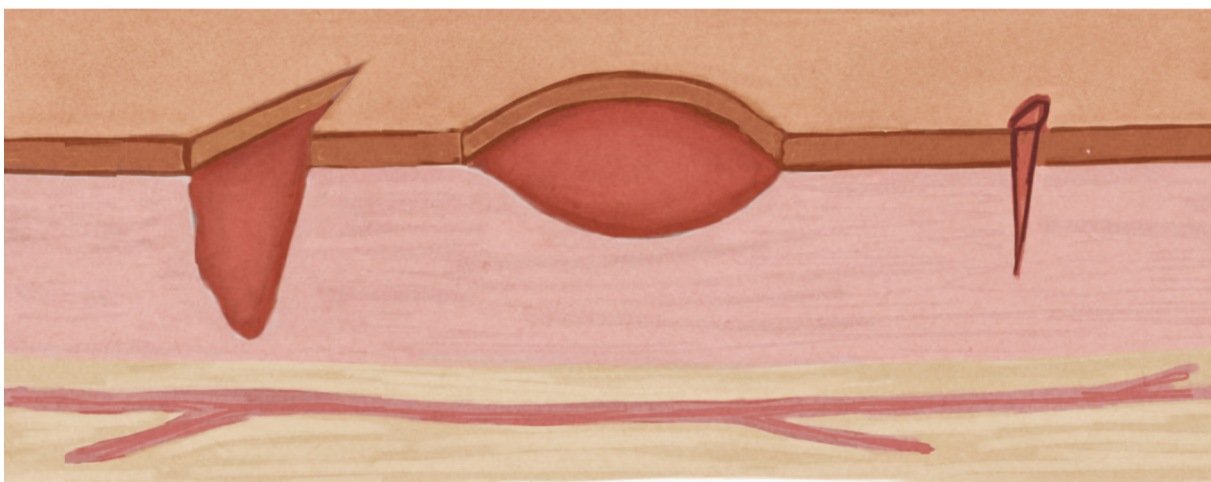
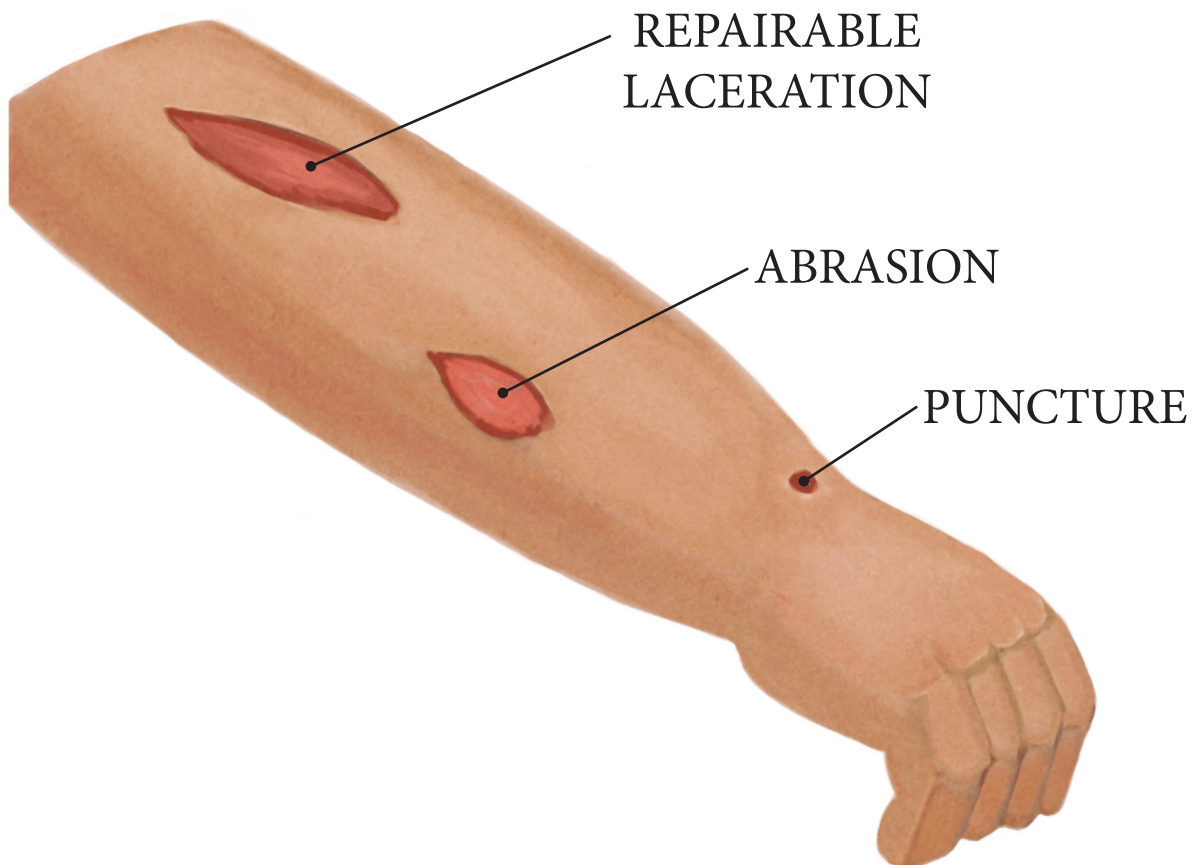
BLOOD DRAW



IV INTRAVENOUS INSERTION



CUT LACERATION



REPAIRABLE
LACERATION

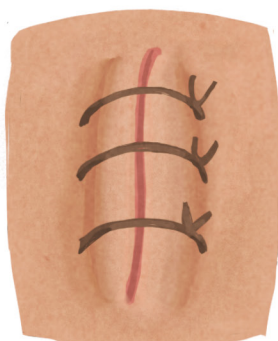
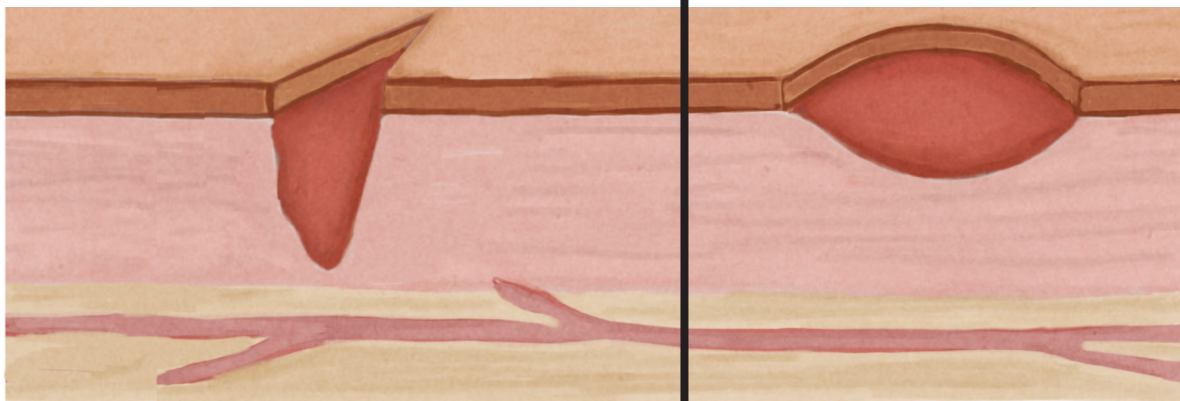
ABRASION

PUNCTURE

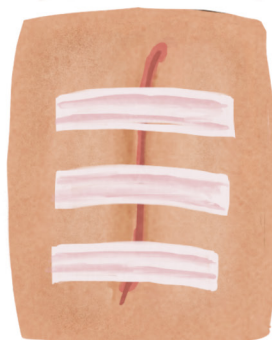
S. ADHIKARI
M.D.

OPTIONS FOR REPAIR

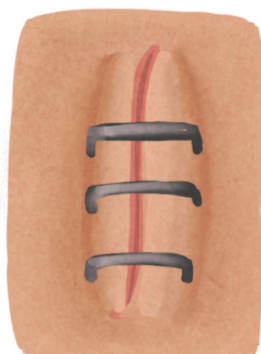LACERATION



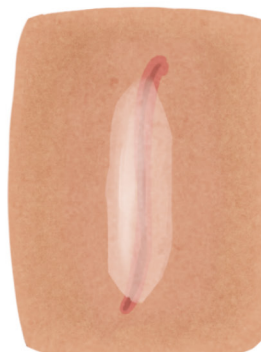STITCHES



STERI-STRIPS

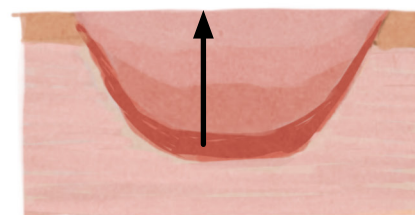
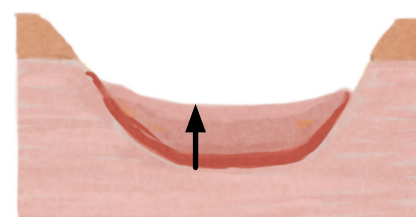
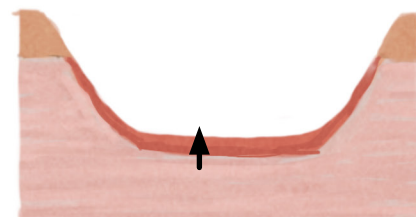


STAPLES



GLUE

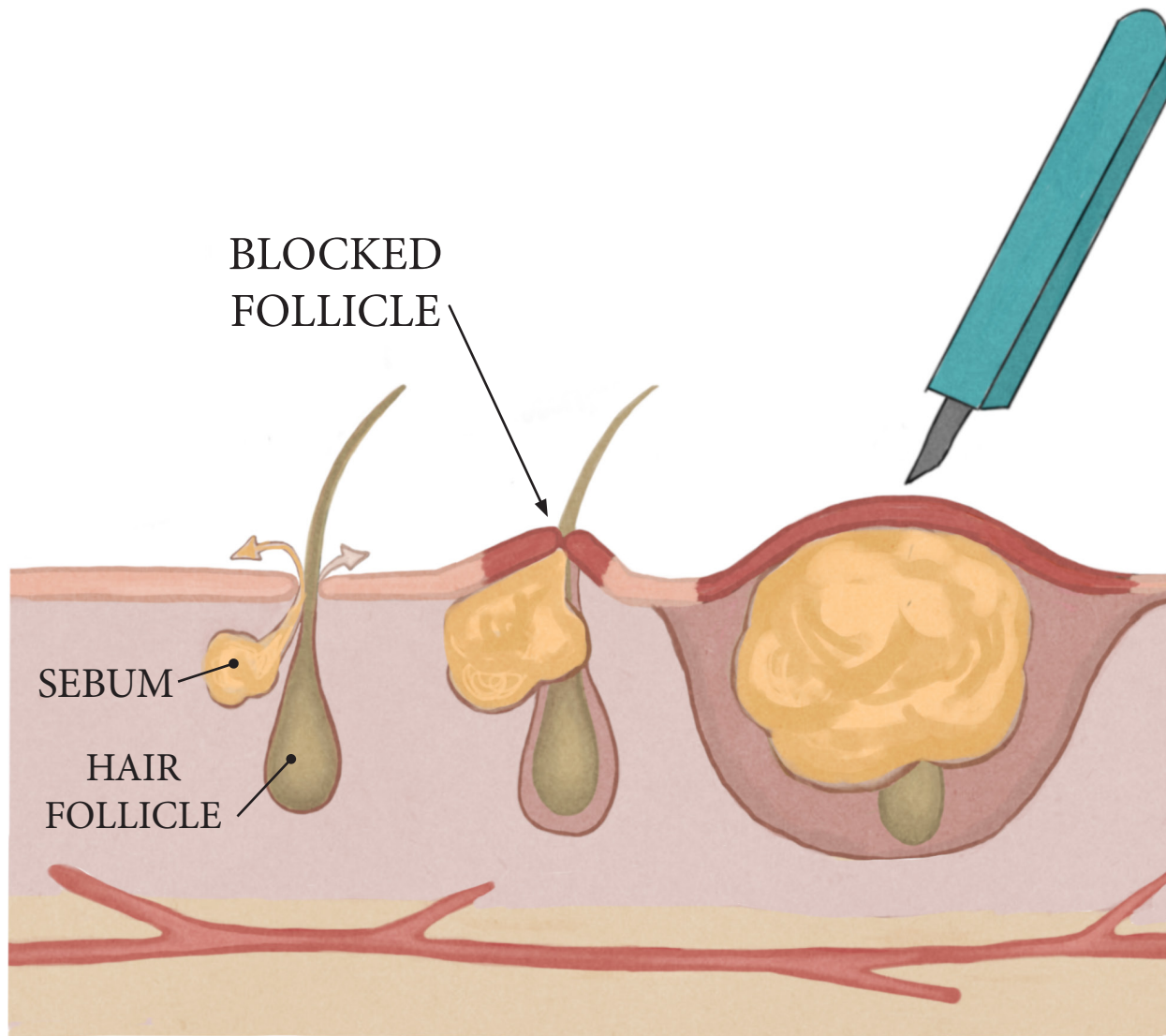
ABRASION



FILLS IN

S. ADHIKARI
M.D.

BOIL ABSCESS



NORMAL

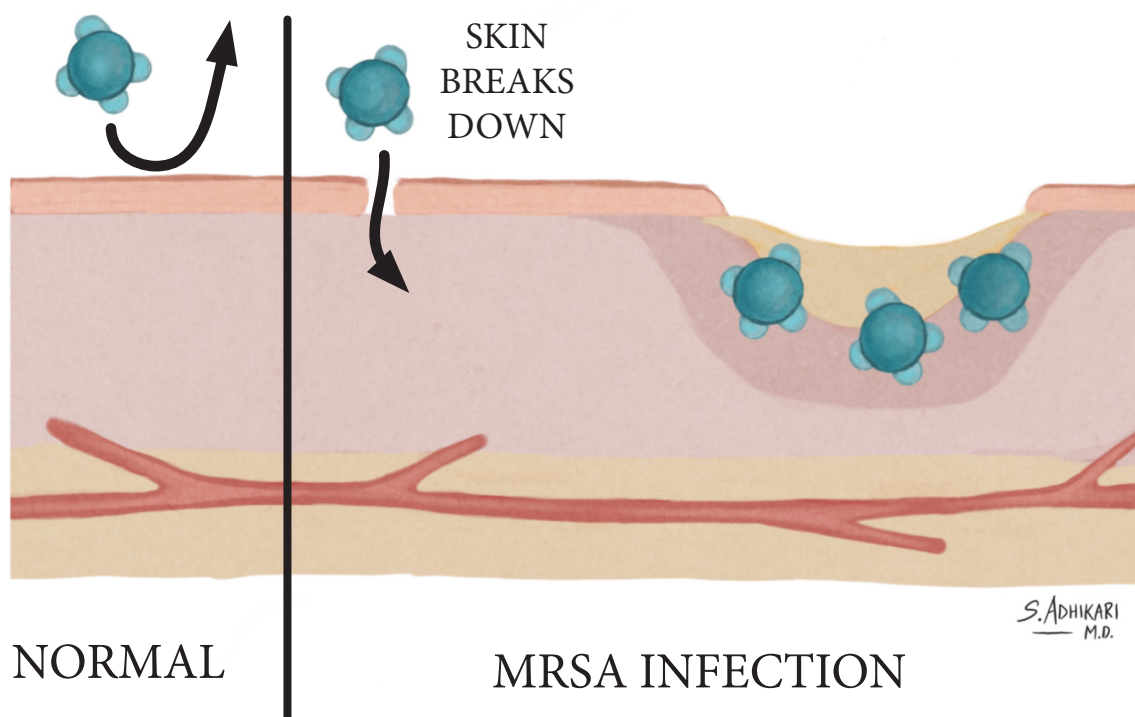
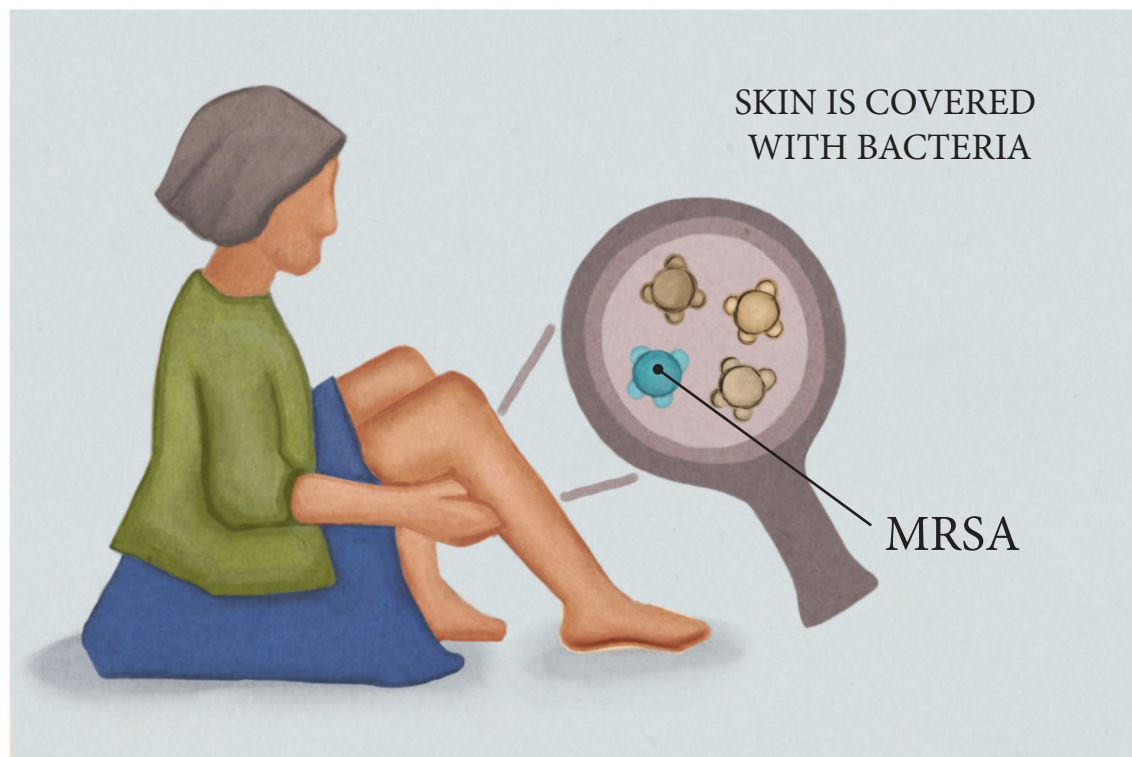EARLY
ABSCESS

LATE
ABSCESS

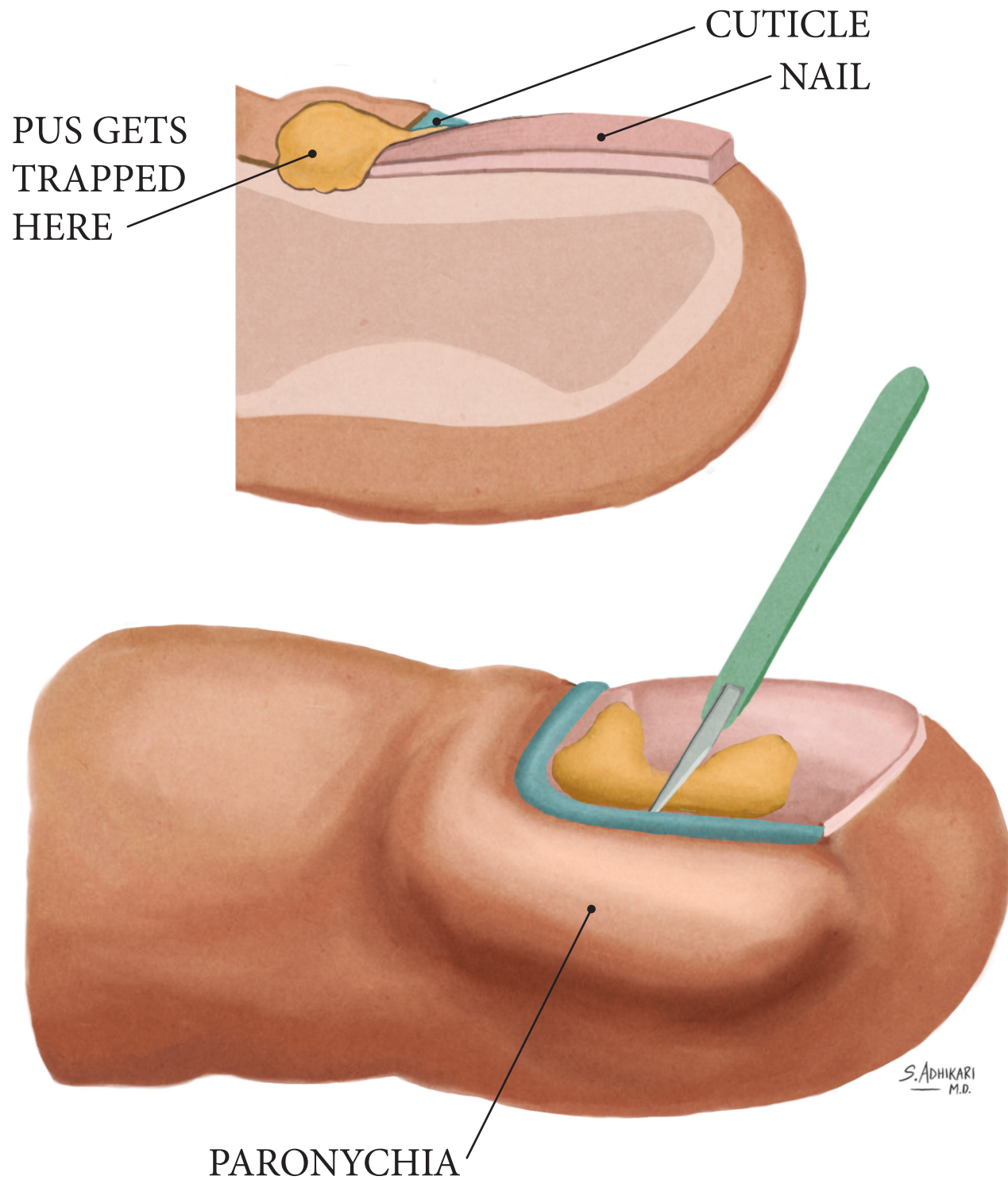
S. ADHIKARI
M.D.

MRSA

METHICILLIN-RESISTANT *STAPHYLOCOCCUS AUREUS*

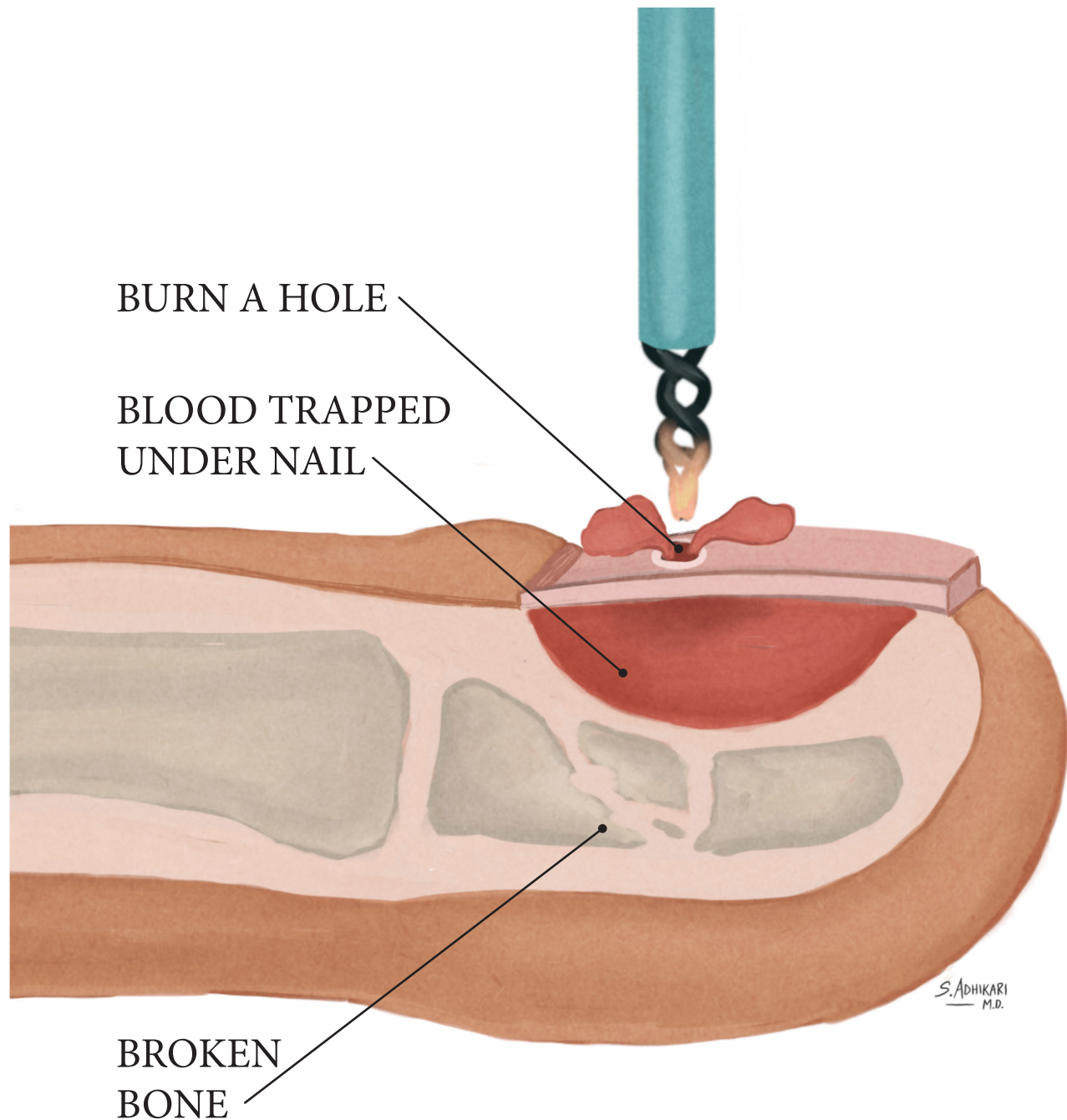


PARONYCHIA



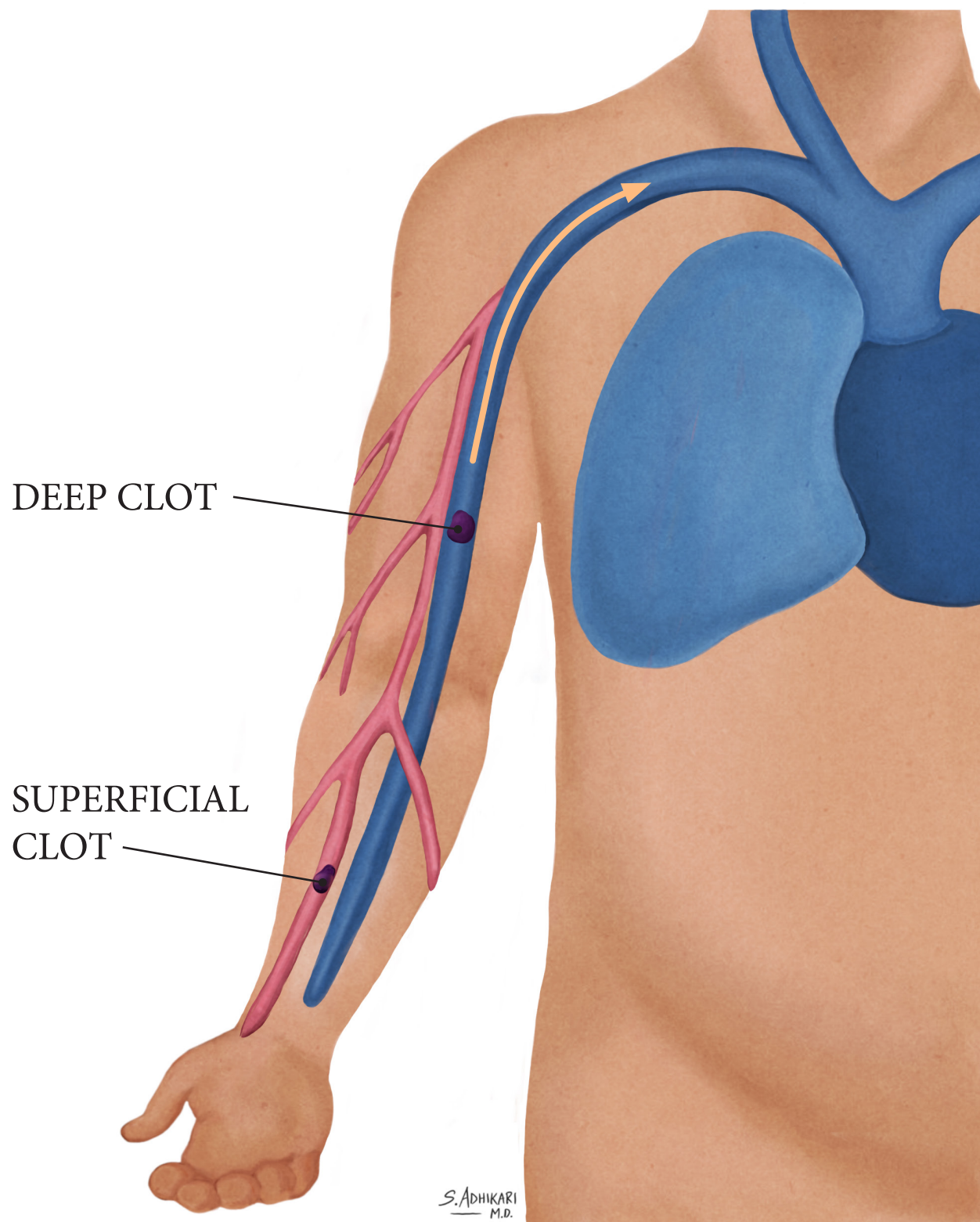
CRUSHED FINGER

SUBUNGUAL HEMATOMA



SUPERFICIAL CLOT

SUPERFICIAL THROMBOPHLEBITIS



AIRWAY ANATOMY

